

case report

Oro-cranial penetrating pencil injury

Shuaib K. Aremu, Muhammed M. Makusid, Ikechukwu C. Ibe

From the Department of Ear, Nose and Throat, Ibrahim Babangida Specialized Hospital, Minna, Niger State, Nigeria

Correspondence: Dr. S. K. Aremu · IBB Specialized Hospital, Minna, Niger State, Nigeria · T: +234-803-358-3842 · shuaib.aremu@gmail.com

Ann Saudi Med 2012; 32(5): 534-536

DOI: 10.5144/0256-4947.2012.30.4.1100

Oro-cranial penetrating injuries are often seen in ear, nose and throat practices. Cases of penetrated pencil injuries are rarely reported despite being common in the developing world. A 7-year-old boy referred from a neighboring hospital was playing at school with the sharp end of a pencil in his mouth when he was pushed from behind by another child. He fell on his face and the sharp end of the pencil penetrated his throat with the distal end hanging out. There was no bleeding at presentation, as the pencil completely sealed the entrance point. The entrance point was at the posterior wall of the oropharynx corresponding to the uvulo-palatine junction. It penetrated posterosuperiorly through the soft tissue to reach the anterior part of the posterior cranial fossa. Since sharp and pointed objects in the upper aerodigestive tract can result in potentially fatal complications, prompt diagnosis, a systematic treatment protocol, and an experienced trauma team are necessary to prevent a potential catastrophe.

Oro-cranial penetrating injuries are often seen in ear, nose and throat (ENT) practices, especially in children. Cases of children inserting a wide variety of household objects into craniofacial orifices are commonplace. The skull and the brain have been reported to be penetrated by a variety of objects, including knife blades, nails, pencils, splinters of wood,¹⁻³ and wire. This could lead to fatal complications. Thus, early presentation and definitive surgical intervention are advocated.

CASE

A 7-year-old boy was referred from a neighboring hospital. He was playing at school with the sharp end of a pencil in his mouth when he was pushed from behind by another child. He fell on his face and the sharp end of the pencil penetrated his throat with the distal end hanging out (Figure 1). No bleeding and no difficulty in breathing were observed at presentation. The physical examination revealed the young boy to be conscious, not pale, with a temperature of 37°C, a respiratory rate of 21/min, and a pulse rate of 86/min. An urgent skull x-ray revealed the shadow of the pencil extending from the oral cavity to the skull base (Figure 2). The packed cell volume was 32%. He was started on intravenous fluid, cefuroxime, and metronidazole. Tetanus toxoid and anti-tetanus injections were given. One unit of

blood was cross-matched and an urgent examination under general anesthesia (GA) was planned for foreign body removal.

Under GA, the mouth and oropharynx were exposed with a Boyle-Davis mouth gag, which revealed the pencil completely sealing its point of entrance (Figure 3). The entrance point was at the posterior wall of the oropharynx corresponding to the uvulo-palatine junction. It penetrated posterosuperiorly through the soft tissue to reach the anterior part of the posterior cranial fossa. A stay suture was placed above and below the

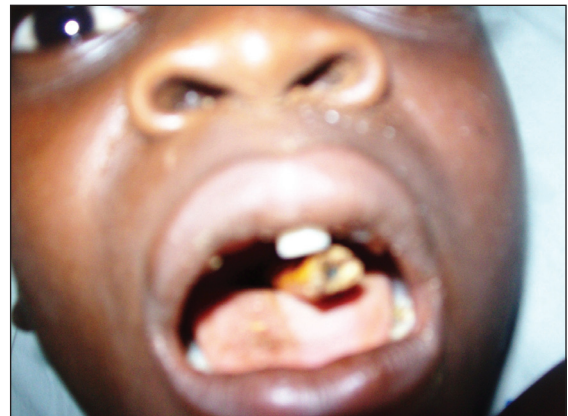


Figure 1. Pencil impacted through oropharynx.

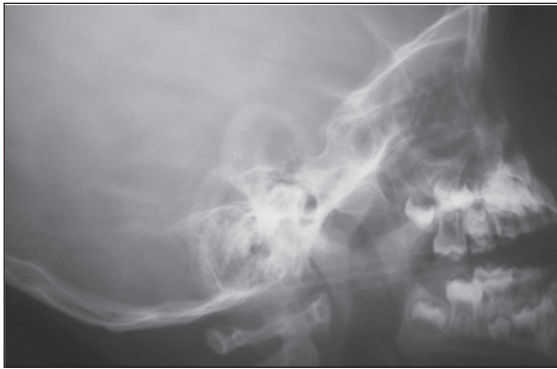

Figure 2. Pencil extending from oral cavity to skull base.



Figure 5. About 7-cm length of the pencil penetrated.

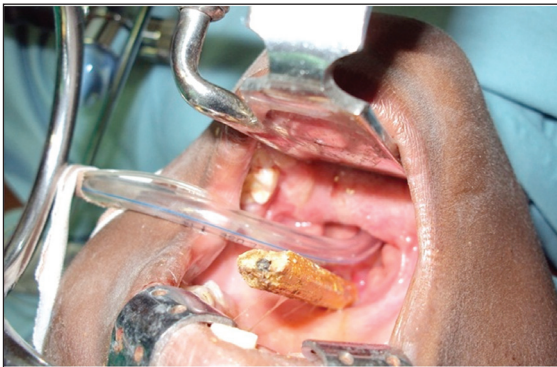

Figure 3. At operation, showing the point of entrance of the pencil.

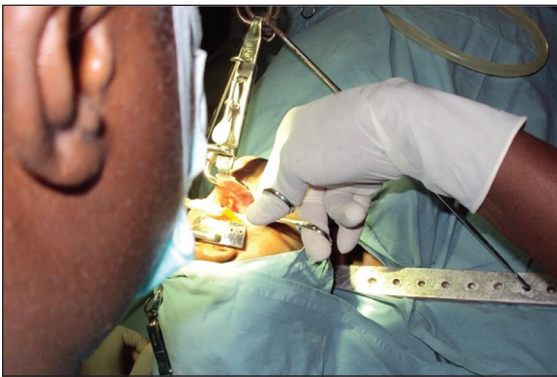

Figure 4. The pencil grabbed with forceps, gently disimpacted and removed.

point of entrance. The pencil was grasped with short foreign body forceps (Figure 4) and gently disimpacted and removed. About 5 mL leakage of cerebrospinal fluid was observed. Firm digital pressure was applied while the stay sutures were then knotted to close the opening. About a 7-cm length of the pencil was embedded (Figure 5). The immediate postoperative condition was satisfactory. Intravenous antibiotics were continued

for 48 hours and changed to oral for 2 weeks. He was discharged on the 5th postoperative day and was monitored in the outpatient clinic for 8 weeks, without features of meningitis or neurological sequelae.

DISCUSSION

Pharyngeal injuries are seen commonly in medical practices, in particular in an emergency medical setting. The typical history is of a sharp object held in the patient's mouth causing an injury after a sudden movement. It is most often seen in pediatric patients.⁴ A significant injury, however, should be suspected even in the case of only minor evidence of injury present to the oropharynx. Patients can present with minimal signs and symptoms. Potential fatal complications such as vascular injuries and infection are reported.⁴ We report a case of an oro-cranial penetrating pencil injury. Although a few cases of oropharyngeal pencil injuries have been reported, this is the first case of oro-cranial penetrating pencil injury in our environment, i.e., north-central Nigeria. One case of brain injury by a ballpoint pen and three cases of transnasal intracranial foreign body have been reported in published studies.⁵⁻⁸ All patients must undergo adequate radiological examination. Plain roentgenograms may yield some information, but may also be misleading. Cranial CT is the best method of evaluation of penetrating brain injuries because it can localize indriven material, give an estimate of the depth, and reveal fractures, intracranial air, and the extent of brain damage.⁹ However, the patient we managed was unable to have a CT scan and had no benefit of being assessed by a neurosurgeon, as none of these are available in the region where we practice. Despite these, he did well with antibiotics after the object was wholly extracted, because no major vascular injury was sustained and no neurological sequelae was observed. Although in our patient the removal was uneventful, this is not always

the case. Most penetrating pencil injuries in children are accidental, but one should be aware of occasional cases of child abuse and suicidal attempts in adults. In most instances, patients are first presented to general practitioners before being referred to specialists, and thus the management of impalement injuries in children should be performed in the following fashion:¹⁰

- + assess the history and clinical scenario;
- + refer the patient for an immediate assessment by a trauma center if the impalement of the object is severe or extrication is likely to bring about complications;

- + careful follow-up is required because of the delayed onset of neurovascular complications; and
- + instruct parents of the possible signs and symptoms of complications.

In conclusion, early and accurate diagnosis of penetrating soft tissue injuries is very important to avoid potential complications. As such emergency cases present at the accident and emergency department, close liaison between the accident and emergency staff and ENT surgeons is vital. Parental counseling is important to prevent their children from playing with sharp objects in their mouths.

REFERENCES

1. Fox JL, Branch JW. Intracranial nail-sets: an unusual self inflicted foreign body. *Acta Neurochir (Wien)* 1971;24:315-8.
2. Miller CF, Brodkey JS, Colombi BJ. The danger of intracranial wood. *Surg Neurol* 1977;7:93-5.
3. Healy JF. Computed tomography of a cranial wooden foreign body. *J Comput Assist Tomogr* 1980;4:555-6.
4. Wu K, Ahmed A. Penetrating injury to the soft palate causing retropharyngeal air collection. *Emerg Med J* 2005;22:148-9.
5. Greene KA, Dickman CA, Smith KA, Kinder EJ, Zabramski JM. Self inflicted orbital and intracranial injury with a retained foreign body, associated with psychotic depression: Case report and review. *Surg Neurol* 1993;40:499-503.
6. Davis E. Two specimens: Abscess in frontal lobe of brain: sinus suppuration. *Proc R Soc Med* 1934;27:1285-8.
7. Stadler HE, Manders K, Marks J, Bonsett C. Recurrent (bilocular) brain abscess due to unusual foreign body, a case report. *J Indiana State Med Ass* 1973;65:799-802.
8. Vandertop WP, de Vries WB, van Swieten J, Ramos LM. Recurrent brain abscess due to an unexpected foreign body. *Surg Neurol* 1992;37:39-41.
9. Bursick DM, Selker RG. Intracranial pencil injuries. *Surg Neurol* 1981;16:427-31.
10. Younessi OJ, Alcaino EA. Impalement injuries of the oral cavity in children: A case report and survey of the literature. *Int J Paediatr Dent* 2007;17:66-71.