



Traumatic Tympanic Membrane Perforation in Tertiary Health Institution

Waheed Atilade Adegbiiji ^{1*} • Gabriel Toye Olajide ² • Oyebanji Anthony Olajuyin ¹
 Fatai Olatoke ³ • Sulyman Abiodun Alabi ⁴ • Clement Chukwuemeka Nwawolo ⁵

¹ Department of Ear, Nose & Throat, Ekiti State University Teaching Hospital, Ado Ekiti, Nigeria

² Department of Ear, Nose and Throat, Federal Teaching Hospital Ido Ekiti/College of Medicine and Health Sciences, Afe Babalola University, Ado Ekiti, Ekiti, Nigeria

³ Department of Ear, Nose & Throat, Federal Medical Centre, Lokoja, Nigeria

⁴ Department of Ear, Nose & Throat, University of Ilorin Teaching Hospital, Ilorin, Nigeria

⁵ Department of Ear, Nose & Throat, Lagos University Teaching Hospital, Lagos, Nigeria

toyeolajide@yahoo.co.uk

ABSTRACT

Background: Traumatic tympanic membrane perforation is a common otologic disorder with associated hearing impairment.

Objective: This study aimed at determining the clinico-epidemiological pattern, etiological factors, clinical presentation and management of traumatic tympanic membrane perforation in a Tertiary institution in Nigeria.

Materials and Methods: This was a prospective hospital based study of patients with history of traumatic perforated of tympanic membrane. The study was carried out over a period of 5 years (September 2012 to August 2017). A study proforma was used to obtain detailed history and clinical findings from consenting patients. Data collected were collated and analyzed using SPSS version 16.0.

Results: Prevalence of traumatic tympanic membrane perforation in this study was 2.1%. There were 65.5% males and 34.5% females with a male to female ratio of 2:1. The common presenting symptoms among the patients were hearing impairment in 68.3%, otalgia in 62.7% and tinnitus in 61.3%. Slap on the ear was the commonest cause of traumatic tympanic membrane perforation in 43.7% of the patients followed by self-ear cleaning in 16.9%. Commonest causes of slap in this study were 15.5% from security agent, 12.7% from seniors/boss while 9.9 % are from spouses. Unilateral traumatic perforation was more common in 97.9% than bilateral in 2.1%. The left ear traumatic perforation was more common than right ear tympanic perforation as 53.5% and 44.4% respectively. Grade 2 in 39.4% was the commonest perforation. Majority of the traumatic perforation were 40.8% central and 33.8% anterior central. Commonest comorbid injuries were subconjunctival hemorrhage in 16.2% and fracture temporal bone in 13.8%. Conductive hearing impairment in 69.7% and sensorineural hearing impairment in 17.6% were the commonest type of hearing impairment in our patients. Commonest degrees of hearing impairment were mild and moderate which accounted for 47.9% and 26.8% respectively. Commonest complications of traumatic tympanic membrane perforation were 68.3% hearing impairment and 26.1% tinnitus. Majority (73.9%) of the patients had conservative/medical therapy and 74.6% traumatic perforation healed at the end of 3 months.

Conclusion: Traumatic perforation arises mainly from direct injuries in this study. The patients tend to present with hearing loss and unilateral involvement is the most common. There is the need to educate the public on the dangers of intentional trauma to the ear

To cite this article

[Adegbiiji, W. A., Olajide, G. T., Olajuyin, O. A., Olatoke, F., Alabi, S. A. & Nwawolo C. C. (2018). Traumatic Tympanic Membrane Perforation in Tertiary Health Institution. *The Journal of Middle East and North Africa Sciences*, 4(01), 8-14]. (P-ISSN 2412- 9763) - (e-ISSN 2412-8937). www.jomenas.org. 2

Keywords: Traumatic, Tympanic Membrane Perforation, Ear Trauma, Ekiti, Hearing Impairment.



1. Introduction:

Tympanic membrane is an oval shape, thin, translucent, gray color membrane situated between external auditory canal and middle ear cleft. It is concave, position obliquely in the medial end of the external auditory canal and form part of the lateral wall of the middle ear cleft (Gacek & Gacek, 2003; Gleeson & Clarke, 2008) Tympanic membrane is divided into two parts by anterior and posterior malleolar folds; the larger lower part is pars tensa and the smaller upper triangular area part is pars flaccid which is devoid of fibrous tissue and annulus (Voss et al., 2007).

Tympanic membrane consists of three layers except in the upper part; outer cuticular layer which is continuous with skin, middle fibrous layer has both circular and radial fibers while inner mucosal layer which is continuous with the middle ear cleft mucosa. Functionally, tympanic membrane transmit sound wave through the ossicles in the middle ear to the inner ear and protects the middle ear cleft from infection (Browning et al., 2008). For normal hearing, an intact tympanic membrane is needed.

Traumatic tympanic membrane perforations are due to direct trauma, acoustic trauma, barotrauma and iatrogenic causes. Traumatic perforations healed spontaneously around 3 months (Dhingra & Dhingra, 2014). It varies in different region and affected by ages, sex and day to day's activities. The trauma includes assault, head injury, slap, faulty technique ear procedure, self-ear cleaning, sport injury such as diving, ear foreign body, explosion, non-pressurized aircraft.

Forces causing traumatic tympanic membrane rupture may also lead to ossicular chain injury, inner ear injury, facial bone fracture, brain injury, orbital injury and so on. Previous studies have reported a wide range of prevalences for traumatic tympanic membrane perforation (9%–47%) among patients injured by explosion (Almogly et al., 2005; Ritenour et al., 2008). There is also increase in violence from political, economic and religious unrest (Ologe & Nwawolo, 2002; Ibekwe et al., 2007; Sarojamma & Satish, 2014).

Traumatic perforation may be classified based on the duration, size, and location of perforation. Traumatic tympanic membrane perforation was said to be acute when it is less 3 months duration while it is chronic perforation when it is more than 3 months duration. Classification based on the size of traumatic perforation depends on the extent of perforation and are divided into small, medium, large, subtotal or total perforation (Hsu et al., 2004; Saliba et al., 2011).

This may also be divided into percentages that ranged from 1-100% or graded from 1-4. Based on the locations of the perforation into central, marginal and attic perforation (Oluwole & Mills, 1996; Ritenour et al., 2008).

Clinical presentation is history of head and neck trauma followed by ear pain, tinnitus, deafness and sense

of ear fullness or blockage. Other associated features include blood-stained ear discharge and vertigo. There was associated fresh blood or blood clot in the external auditory canal. Examination revealed irregular and congested margins of the membrane.

Management of traumatic tympanic membrane perforation must include management of comorbid injuries. It is a source of great concern for otorhinolaryngologists to restore completely the structural and functional integrity of tympanic membrane with associated comorbid injuries (Ologe, 2002; da Lilly-Tariah & Somefun, 2007). There is paucity of literature on traumatic perforation of the tympanic membrane in developing countries and Nigeria in particular. This study aimed at determining the clinico-epidemiological pattern, aetiological factors, clinical presentation and management of traumatic tympanic membrane perforation in Ekiti, Nigeria.

2. Materials and Methods:

This was a prospective hospital based study of patients with history of traumatic tympanic membrane perforation. The study was conducted in ear, nose and throat department of Ekiti state university teaching hospital Ado Ekiti, Nigeria. The study was carried out over a period of 5 years (September 2012 to August 2017).

Informed consent was obtained from patients/parents/guardian and consented patients were enrolled into the study. All patients with clinical history/findings of traumatic tympanic membrane perforation were enrolled into the study. Detailed clinical history and examination were obtained from patients using interviewer assisted questionnaire. The data obtained were on sociodemographic features (such as age, sex, occupation). Detailed data were also obtained on ear symptoms such as hearing loss, tinnitus, itching, ear pain, vertigo, ear discharge and duration of symptoms. History of causes, predisposing factors, past illness, ear picking, ototoxic drugs, ear trauma and ear instrumentation/surgery were obtained.

Detailed ear examination and tympanic membrane perforation assessment was done by otoscope /microscope. Eardrum perforation grading was made by estimating the relative size of the perforations: A grade 1 traumatic perforation was defined as a pinpoint or linear tear up to 2 mm, grade 2 involved small perforation less than 25% of the tympanic membrane, grade 3 involved medium perforation 25% to 50% of the tympanic membrane and grade 4 large traumatic perforation more than 50% of the tympanic membrane.

Pure Tone Audiometry were determined for air and bone conductions at 500, 1000, 2000, and 4000 Hz. Radiological examination was done for extent skull fracture. A conservative management approach was adopted for uncomplicated perforation. When there was

associated bloody or watery discharge, nasal decongestant, and oral/systemic antibiotics to prevent infection. The patients were advised to keep ear dry. All patients were advised to present if ear discharge was noticed. All the patients were then follow-up and assessed in the clinic.

Data collected were collated and analyzed using SPSS version 16.0. The data were expressed by table, percentage, bar charts and pie charts. Ethical clearance was obtained from the Ethics and Research Committee of the institution.

3. Results:

A total of 6771 patients were seen in the department during the study period out of which 142 patients had traumatic tympanic membrane perforation. The incidence of traumatic tympanic membrane perforation in this study was 2.1%.

Traumatic tympanic membrane perforation occurred in all the studied age groups. Figure 1 illustrates the age group distribution of patients with traumatic tympanic membrane perforation.

There were 93 (65.5%) males and 49 (34.5%) females with male to female ratio of 2:1. Urban resident patients accounted for 83 (58.5%) while rural resident accounted for 59 (41.5%). Commonest affected educational level were primary and secondary level in 49 (34.5%) and 36 (25.4%) respectively. Others were preschool in 33 (23.2%) and post-secondary in 24 (16.9%). On patient's occupation, commonest were students/apprentice in 53 (37.3%) this was followed by driver in 27 (19.0%). Table 1 demonstrated sociodemographic features of patients with tympanic membrane perforation. The most common presenting symptom among the patients were hearing impairment in 97 (68.3%), otalgia in 89 (62.7%) and tinnitus in 87 (61.3%). Other presenting symptoms are aural fullness in 72 (50.7%) and otorrhea 70 (50.0). This is showed in figure 2.

In this study, slap on the ear was the commonest cause of traumatic tympanic membrane perforation in 62 (43.7%) followed by self ear cleaning in 24 (16.9%). Other causes were road traffic accident and untrained ear procedure and were 21 (14.8%) and 18 (12.7%). This is illustrated in figure 3.

Commonest causes of slap in this study were from security agent in 22 (15.5%), seniors/bosses in 18 (12.7%) and 14 (9.9%) from spouses. Figure 4 showed sources of slap in patients with traumatic tympanic membrane perforation.

Unilateral traumatic tympanic membrane perforation was recorded in 139 (97.9%) of the patients while 3 (2.1%) had bilateral perforation. The left ear traumatic tympanic membrane perforation was more common than right ear tympanic membrane perforation and respectively accounted for 76 (53.5%) and 63 (44.4%) respectively. Grade 2 traumatic tympanic membrane

perforation was 56 (39.4%) and predominant over grade 1 and grade 3 perforations which were 43 (30.3%) and 36 (25.4%) respectively. In this study, majority of the traumatic tympanic membrane perforation were central in 58 (40.8%) anterior central in 48 (33.8%) and posterior central in 29 (20.4%). The less common site of tympanic membrane perforation was 3 (2.1%) marginal and 4 (2.8%) attic perforations. Sub-conjunctival hemorrhage in 23 (16.2%), fracture temporal bone in 21 (13.8%) and fracture facial bone in 16 (11.3%) were the commonest associated comorbid injuries in patients with traumatic tympanic membrane perforation in this study. This is illustrated in table 2.

Major sources of referral were general practitioners and pediatricians which were 52 (36.6%) and 32 (22.5%) respectively. Minor referral was from casualty officer in 24 (16.9%) and self-reporting 23 (16.2%). Figure 5 demonstrated sources of referral of the patients with tympanic membrane perforation.

In this study, conductive hearing impairment is the commonest type of hearing impairment and accounted for 99 (69.7%) others were sensorineural hearing impairment in 25 (17.6%) and mixed hearing impairment in 18 (12.7%). The commonest degree of hearing impairment were mild, and moderate, which accounted for 68 (47.9%) and 38 (26.8%) respectively. Other degree of hearing impairment in this study are moderate-severe and severe in 16 (11.3%) and 3 (2.1%) respectively. This is further demonstrated in table 3.

Commonest complications of traumatic tympanic membrane perforation were hearing impairment in 97 (68.3%) others were 37 (26.1%) tinnitus and 34 (23.9%) acute suppurative otitis media. Majority of treatment offered to the patients were conservative/medical therapy in 105 (73.9%) followed by minor surgery in 28 (19.7%). Those patients with healed tympanic membrane perforation at the end of 3 months were 106 (74.6%) while those with non-healed tympanic membrane perforation after 3 months were 21 (14.8%). The detailed is showed in table 4.

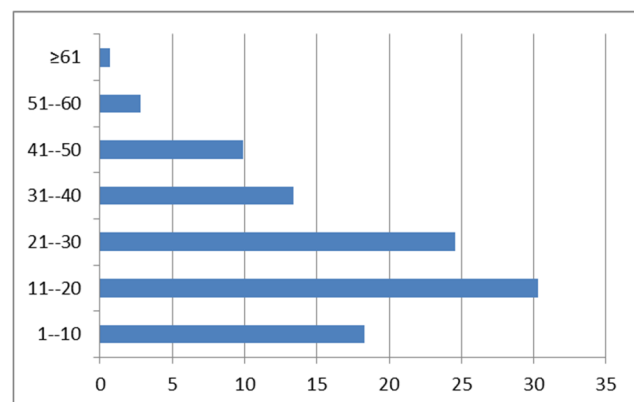


Figure 1. Age group (years) distribution of the patients with traumatic tympanic membrane perforation



Table 1. Sociodemographic features of patients with traumatic tympanic membrane perforation.

Sociodemographic features	Number	Percentage (%)
Sex		
Male	93	65.5
Female	49	34.5
Residential		
Urban	83	58.5
Rural	59	41.5
Education level		
Preschool	33	23.2
Primary	49	34.5
Secondary	36	25.4
Post-secondary	24	16.9
Patients occupation		
Student/Apprentice	53	37.3
Applicant	17	12.0
Business	2	1.4
Driver	27	19.0
Industrial worker	11	7.7
Farming	11	7.7
Artisans	21	14.8

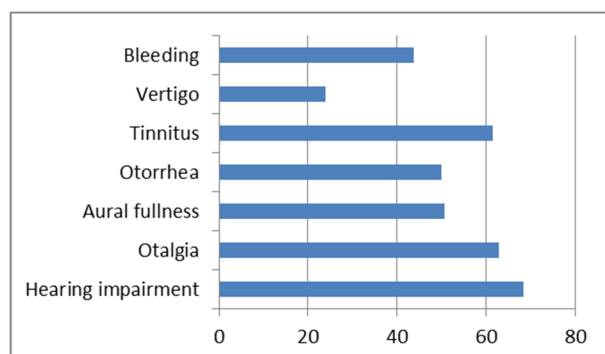


Figure 2. Clinical features of the patients with traumatic tympanic membrane perforation.

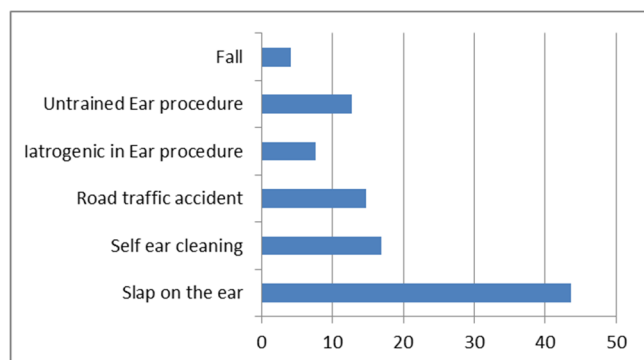


Figure 3. Etiology of traumatic tympanic membrane perforation among the patients.

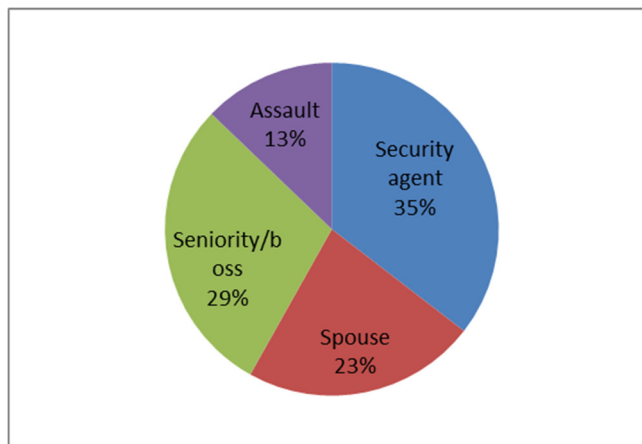


Figure 4. Sources of slap in patients with traumatic tympanic membrane perforation

Table 2. Features of traumatic tympanic membrane perforation among the patients.

Features	Number	Percentage (%)
Lateralization		
Left	76	53.5
Right	63	44.4
Bilateral	3	2.1
Size		
Grade 1	43	30.3
Grade 2	56	39.4
Grade 3	36	25.4
Grade 4	7	4.9
Location		
Attic	4	2.8
Central	58	40.8
Marginal	3	2.1
Anterior central	48	33.8
Posterior central	29	20.4
Comorbid head/neck injuries		
Subconjunctival hemorrhage	23	16.2
Fracture facial bone	16	11.3
Fracture temporal bone	21	13.8
Cerebrospinal fluid otorrhea	9	6.3
Facial nerve palsy	11	7.7

4. Discussion:

Traumatic tympanic membrane perforation is one of the common otorhinolaryngological presentations in clinical practice worldwide. The prevalence of traumatic tympanic membrane perforation in this study was 2.1%. This may be due to under reporting of patients to our department. Higher prevalence was recorded in other studies (Almogly et al., 2005; Ritenour et al., 2008).

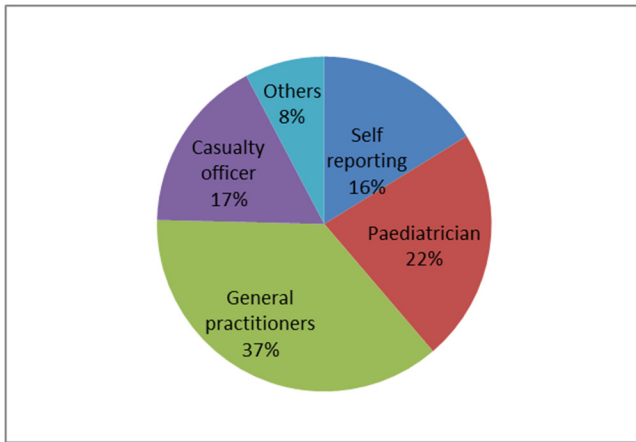


Figure 5. Sources of referral among patients with traumatic tympanic membrane perforation

Table 3. Pattern of hearing impairment among patients with traumatic tympanic membrane perforation.

Hearing impairment	Number	Percentage (%)
Type of hearing impairment		
Conductive	99	69.7
Sensorineural	25	17.6
Mixed	18	12.7
Degree of hearing impairment		
Normal (<26dB)	17	12.0
Mild (26-40dB)	68	47.9
Moderate (41-55dB)	38	26.8
Moderate-severe (56-70dB)	16	11.3
Severe (71-90dB)	3	2.1
Profound (>90dB)	0	0

Table 4. Management of patients with traumatic tympanic membrane perforation.

Treatment duration	Number	Percentage (%)
Complications		
Hearing loss	97	68.3
Tinnitus	37	26.1
Acute suppurative otitis media	34	23.9
Chronic suppurative otitis media	22	15.5
Aural granulation/polyps	4	2.8
Treatment offered		
Conservative therapy	105	73.9
Minor surgery	28	19.7
Referral	9	6.3
Treatment outcome		
Healing after 3 months	106	74.6
Non-healing after 3 months	21	14.8
Loss to follow up	15	10.6

Prevalence of traumatic tympanic membrane perforation was found to be higher among the young, active and males patients in this study. This finding is similar to

record from other study (Sarojamma, & Satish, 2014; Rabbani et al., 2015).

In this study traumatic perforation is more common among the people of lower economic class such as students/apprentice and driver. This is in agreement with other study (Rabbani et al., 2015). This is expected, as traumatic perforation is commoner in this group of patients as similar findings were recorded in other series (Ologe, 2002; da Lilly-Tariah & Somefun, 2007). Past record revealed trauma to the tympanic membrane and the middle ear are commonly due to overpressure, thermal or caustic burns blunt or penetrating injuries, and barotraumas (Ijaduola 1986; Rasool et al., 2016)

In this study overpressure such as slap, self ear cleaning and road traffic accidents were the most common causes of traumatic tympanic membrane perforation and in agreement with studies elsewhere (Ladapo, 1979; Ijaduola & Okeowo, 1986).

This study shows that majority of the traumatic perforated tympanic membrane was caused by slap from security agents others were spouse and seniority or boss. This is similar to findings in other study (Sarojamma & Satish, 2014).

In this study left ear traumatic perforation was more common than right ear because left ear was slapped by right hand. Right handed people are commoner than left handed making the left ear more vulnerable to trauma (Lou et al., 2012; Wani et al., 2016).

This is in keeping with recorded value from similar study (Sarojamma & Satish, 2014). In this study smaller grade 1 and 2 traumatic tympanic membrane perforation were more common than other grades of traumatic perforation. In another study their finding was predominated with larger perforations (Shrivastav, 2006). From this study it is clear that rupture is solely in the central, anterior central and posterior central portions of the pars tensa of tympanic membrane. The central portion is more predisposed to rupture from pressure because is the most dependent part of the tympanic membrane (Ediale et al., 2017).

Forces lead to traumatic perforation may lead to comorbid injuries in the head and neck region. The commonest associated comorbid injuries in this study include subconjunctival hemorrhage, fracture temporal bone, and fracture facial bone. Common clinical presentation of traumatic perforation was hearing impairment followed by tinnitus and earache. The degree of hearing impairment depends on extent of rupture and associated damage. This finding is similar to record in other studies (Afolabi et al., 2009; Onyeagwara et al., 2014; Raj et al., 2016)

In this study conductive hearing loss is commoner than sensorineural hearing loss and mixed hearing loss in the patients. This is due to loss of ossicular coupling in perforation of the tympanic membrane which usually

causes a loss that ranges from negligible to 50 dB (Manolidis, 2003).

In this study, hearing loss increased with increase in size of perforation at each frequency due to hydraulic action arising from the difference in area of foot plate (Ahmad & Ramani, 1979). When the surface area decreased, there is decrease in amplification and hearing loss will be proportional to the size of perforated tympanic membrane (Chun et al., 2010). Furthermore in this study, pure tone audiometric results showed no differences or mild variations in the air-bone gaps at any frequency with relation to the location of perforation i.e. anterior vs. posterior perforation. Contrary to widely held clinical view that posterior perforations result in larger hearing losses than anterior perforations.

On the sources of referral of patients with tympanic membrane perforation to otorhinolaryngologists, head and neck surgeon for expert review and management in this study were mainly from general practitioners and pediatrician followed by casualty officer. This may be because these are first contact with the patients for treatments or because of their predominant over ear, nose and throat surgeon.

In this study, majority of the patients were managed with conservative/medical treatment. This is because traumatic tympanic membrane perforations commonly occur in healthy eardrum and the prognosis is excellent with conservative management only. This finding is similar to findings in other studies (Santhi & Rajan, 2012; Hegazy, 2013). Factors that prevent or delay healing of perforated tympanic membrane are extent of ruptured, loss of tissue and secondary infection. Common complications of traumatic perforation in this study were acute and chronic suppurative otitis media. This is also reported in other studies (Rehman et al., 2012).

Uninfected ear must be kept dry and observed for at least 3 months. Persistent dry perforated eardrums for at least 3 months in this study were scheduled for surgical intervention such as myringoplasty and cauterization. Some of the patients were referred to other center with required facilities for further surgical intervention.

5. Conclusion:

Traumatic tympanic membrane perforation is a common otological condition mainly from ear trauma. Traumatic perforation arises mainly from direct injuries. The patients tend to present with hearing loss and unilateral involvement is the most common. There is the need to educate the public on the dangers of intentional trauma to the ear.

Financial support and sponsorship:

Nil.

Conflicts of interest:

There are no conflicts of interest.

Corresponding Author:

Gabriel Toye Olajide, MBBS, FWACS, FMCORL.
Department of Ear, Nose and Throat, Federal Teaching Hospital Ido Ekiti/College of Medicine and Health Sciences, Afe Babalola University, Ado Ekiti.
E-mail: toyeolajide@yahoo.co.uk

References:

- Ahmad, S. W., & Ramani, G. V. (1979). Hearing loss in perforations of the tympanic membrane. *The Journal of Laryngology & Otolaryngology*, 93(11), 1091-1098.
- Afolabi, O. A., Aremu, S. K., Alabi, B. S., & Segun-Busari, S. (2009). Traumatic tympanic membrane perforation: an aetiological profile. *BMC research notes*, 2(1), 232.
- Almogly, G., Luria, T., Richter, E., Pizov, R., Bdolah-Abram, T., Mintz, Y., ... & Rivkind, A. I. (2005). Can external signs of trauma guide management? Lessons learned from suicide bombing attacks in Israel. *Archives of Surgery*, 140(4), 390-393.
- Browning, G. G., Gleeson, M., & Burton, M. J. (2008). *Scott-Brown's otolaryngology-head and neck surgery*. 7th edn. Vol. 3.
- Chun, S. H., Lee, D. W., & Shin, J. K. (2010). A Clinical Study of Traumatic Perforation of Tympanic Membrane. Seoul, Korea: Department of Otolaryngology, *Hanil General Hospital*, 113, 679-86.
- da Lilly-Tariah, O. B., & Somefun, A. O. (2007). Traumatic perforation of the tympanic membrane in University of Port Harcourt Teaching Hospital, Port Harcourt. Nigeria. *The Nigerian postgraduate medical journal*, 14(2), 121-124.
- Dhingra, P. L., & Dhingra, S. (2014). *Diseases of Ear, Nose, and Throat-E-Book*. Elsevier Health Sciences.
- Ediale, J., Adobamen, P. R. C., & Ibekwe, T. S. (2017). Aetiological factors and dimension of tympanic membrane perforation in Benin City, Nigeria. *Port Harcourt Medical Journal*, 11(2), 55.
- Gacek, R. R., & Gacek, M. R. (2003). Anatomy of the auditory and vestibular systems. *Ballenger's Otorhinolaryngology Head and Neck Surgery*, 1, 1-5.
- Gleeson, M. J., & Clarke, R. C. (Eds.). (2008). *Scott-Brown's Otorhinolaryngology: Head and Neck Surgery* 7Ed: 3 volume set. CRC Press.
- Hegazy, H. M. (2013). Fat graft myringoplasty—A prospective clinical study. *Egyptian Journal of Ear, Nose, Throat and Allied Sciences*, 14(2), 91-95.
- Hsu, C. Y., Chen, Y. S., Hwang, J. H., & Liu, T. C. (2004). A computer program to calculate the size of tympanic membrane perforations. *Clinical Otolaryngology*, 29(4), 340-342.
- Ibekwe, T. S., Ijaluola, G. T. A., & Nwaorgu, O. G. (2007). Tympanic membrane perforation among adults in West Africa. *Otology & Neurotology*, 28(3), 348-352.

14. Ijaduola, G. T. A. (1986). The principles of management of deafness. *Nig Med Pract*, 12, 19-25.
15. Ijaduola, G. T. A., & Okeowo, P. A. (1986). Foreign body in the ear and its importance: the Nigerian experience. *Journal of tropical pediatrics*, 32(1), 4-6.
16. Ladapo, A. A. (1979). The danger of foreign bodies in the ear. *Nigerian medical journal: journal of the Nigeria Medical Association*, 9(1), 120-122.
17. Lou, Z. C., Lou, Z. H., & Zhang, Q. P. (2012). Traumatic tympanic membrane perforations: a study of etiology and factors affecting the outcome. *American journal of Otolaryngology*, 33(5), 549-555.
18. Manolidis, S. (2003). *Closure of tympanic membrane perforations*. Glasscock-Shambaugh surgery of the ear. 5th ed. Ontario: BC Decker, 400-19.
19. Ologe, F. E. (2002). Traumatic perforation of the tympanic membrane in Ilorin, Nigeria. *Nig j Surg*, 8(1), 9-12.
20. Ologe, F. E., & Nwawolo, C. C. (2002). Prevalence of chronic suppurative otitis media (CSOM) among school children in a rural community in Nigeria. *The Nigerian postgraduate medical journal*, 9(2), 63-66.
21. Oluwole, M., & Mills, R. P. (1996). Tympanic membrane perforations in children. *International journal of pediatric otorhinolaryngology*, 36(2), 117-123.
22. Onyeagwara, N. C., Okhakhu, A. L., & Braimah, O. E. (2014). A Retrospective Study of Traumatic Tympanic Membrane Perforation at the University of Benin Teaching Hospital, Nigeria. *Annals of Biomedical Sciences*, 13(1), 83-92.
23. Rabbani, S. G., Rashid, M. A., Mahmud, K., Chowdhury, M. A., & Razzak, M. A. (2015). Traumatic Rupture of Tympanic Membrane: A Study of 70 Cases. *Bangladesh Journal of Otorhinolaryngology*, 21(1), 38-42.
24. Raj, R., Meena, S.K., Meena, D.R., & Meena, M. (2016). A study on the fate of traumatic tympanic membrane perforation. *Indian Journal of Anatomy & Surgery of Head, Neck & Brain*, 2(3):76-78.
25. Rasool, S., Ahmad, F., & Ahmad, R. (2016). Traumatic tympanic membrane perforations: an overview in tertiary care hospital. *The Egyptian Journal of Otolaryngology*, 32(3), 187.
26. Rehman, A., Hamid, S., Sangoo, M., Akhter, M., & Hamid, S. (2012). Pattern of hearing loss from otological trauma due to non-explosive blast injury caused by slap to the ear in Kashmiri population. *Otolaryngology*, 2(4).
27. Ritenour, A. E., Wickley, A., Ritenour, J. S., Kriete, B. R., Blackbourne, L. H., Holcomb, J. B., & Wade, C. E. (2008). Tympanic membrane perforation and hearing loss from blast overpressure in Operation Enduring Freedom and Operation Iraqi Freedom wounded. *Journal of Trauma and Acute Care Surgery*, 64(2), S174-S178.
28. Saliba, I., Abela, A., & Arcand, P. (2011). Tympanic membrane perforation: size, site and hearing evaluation. *International journal of pediatric otorhinolaryngology*, 75(4), 527-531.
29. Santhi, T., & Rajan, K. V. (2012). A study of closure of tympanic membrane perforations by chemical cauterization. *Indian Journal of Otolaryngology and Head & Neck Surgery*, 64(4), 389-392.
30. Sarojamma, D. S. R., & Satish, H. S. (2014). A clinical study of traumatic perforation of tympanic membrane. *IOSR Journal of Dental and Medical Sciences*, 13(4), 24-28.
31. Shrivastav, R. P. (2006). Size of tympanic membrane perforation and hearing loss. *J Nep Med assoc*; 45: 167-172
32. Voss, S. E., Rosowski, J. J., Merchant, S. N., & Peake, W. T. (2007). Non-ossicular signal transmission in human middle ears: experimental assessment of the "acoustic route" with perforated tympanic membranes. *The Journal of the Acoustical Society of America*, 122(4), 2135-2153.
33. Wani, A., Rehman, A., Lateef, S., Malik, R., Ahmed, A., Ahmad, W., & Kirmani, M. (2016). Traumatic tympanic membrane perforation: An overview. *Indian Journal of Otology*, 22(2), 100.

Received November 29, 2017; revised December 09, 2017; accepted December 12, 2017; published online January 01, 2018