

Effects of *Acalypha torta* (Muell) Leaf Extract on Histological Indices of the Visceral Organs of Male (*Rattus norvegicus*) Wistar Rats

* Odigie, B.E.¹, Erameh, T.O.², Ekundina, V.O.³

¹Department of Medical Laboratory Science, School of Basic Medical Science, College of Medical Science, University of Benin, P.M.B.1154, Benin City, Nigeria.

²Department of Medical Laboratory Science, Faculty of Health Science and Technology, University of Nigeria, Enugu, Nigeria.

³Department of Medical Laboratory Science, Faculty of Basic Medical Science, Afe Babalola University, Ado-Ekiti, Nigeria.

ABSTRACT: *Acalypha torta* (Muell) a lush ornamental plant is commonly used for the treatment of fungal skin diseases, pain, fever, and ulcer. It is used by traditional herbal practitioners in Nigeria without a safe dose regimen. For this reason, the present study examines the histological indices (cyto-architecture) in rats treated orally with *A. torta* crude leaf aqueous extract. Thirty male Wistar rats with average weight (202.25g) were assigned to 5 groups (n=6). The animals were acclimatized under a standard ambient temperature of 26-28°C. Food and water were provided as required. Extracts between 50mg/ml to 500mg/ml were administered to the rats in group (A, B, C and D) orally while E served as the untreated group. All rats were sacrificed by (Chloroform) anesthetization at the termination of the experiment. Grossing was done following excision of visceral organs of interest (liver and kidney). Cut tissue at 3-5mm was processed histologically and was sectioned at 3-5microns. Mayer's haematoxylin and eosin stained sections were examined using the light microscope. The results showed normal histological indices of the liver and kidney examined. Though there were negligible signs of acute histopathology effects but were thought to be dose-related offenses. Therefore, the present study provides support for the safety profile of *A. torta* herbal preparation in a concentration of 500mg/ml in male Wistar rats. However, further studies may attempt to look at higher doses under similar circumstances.

KEYWORDS: *Acalypha* species, cyto-architecture, histological indices, kidney, and liver.

I. INTRODUCTION

The use of plants and plant extracts as trado-medical relief has been in existence for ages. This practice has been encouraged in recent times due to the less frequent side effects when compared with orthodox medicine [1]. There has been growing interest in the investigation of the alternative route for the substitution of synthetic chemicals side effects, which are always in question [2]. Irrespective of the successes achieved using technology, the intuitive individuals across different geographical terrain especially developing countries still continue to use herbs for the treatment of certain ailments, either as a result of poverty or the efficacy of the herbal products [3].

Acalypha torta (Muell) plant is one of such medicinal plant that has been in existence for ages with a full exploration of its medicinal values. It belongs to the family Euphorbiaceae which is a family of dicotyledonous plants that include shrubs and trees. They are primarily found in the tropical region of Africa [1]. The leaves are used medicinally for the treatment of some fungal skin diseases, fever, and ulcer. The plant is also useful traditionally in the treatment of neonatal jaundice [4, 5]. However, detailed description, distribution and the general use of *A. torta* plant has been documented [1]. In spite of the numerous medicinal values of *A. torta* in circulation across the world, there appears to be scant or no information on the effects on histological indices of the visceral organs (liver and kidney) of albino rats from this cultivar. By our knowledge, this may be the first of its kind. Conversely, lack of scientific proof of efficacies claimed by charlatans in the herbal trado-medical practice also calls for concern. Therefore, the present study examines the histological indices (cyto-architectures) of the visceral organs of male Wistar rats treated with *A. torta* leaf extract orally.

II. MATERIALS AND METHODS

The present study was experimental, with the use of an animal model. Approval for the study was granted by the ethics and research committee, Faculty of Pharmacy, University of Benin, Benin City, Nigeria.

2.1 Plant Collection and Authentication

The leaves of *A. torta* were obtained at a privately owned horticultural garden in Benin City. It was identified at the Department of Plant Biology and Biotechnology, Faculty of Life Science, University of Benin, Nigeria. The plant material was authenticated by the Department of Pharmacognosis, Faculty of Pharmacy, University of Benin, Nigeria. A sample plant was deposited at the Departmental herbarium of the former.

2.2 Extract Preparation

The plant leaves were air-dried at room temperature (29°C) in the Laboratory and pulverized into uniform fine powdered particle and sieved. Two hundred grams of the powdered leaf was soaked in 1 liter of distilled water for 48 hours on laboratory bench. Filtration under suction pressure was done with a Whatman's filter paper. After that, water was removed by the freeze drier (Modulyo, Edwards) for 12h while the powdered extract was stored at 4°C for experimental use. To ensure the preservation of the active phytochemical properties of the plant, fresh aqueous extract was prepared every-other day. The dried down extract was reconstituted in distilled water for animal oral treatment by using 2g of the concentrated plant filtrate, dissolved in 20ml of distilled water to give a concentration of 100mg/ml^[6].

2.3 Experimental Animals

Thirty inbred male Wistar rats with a mean weight of 202.25g were housed in a wire gauze cages. Already acclimatized rats in the fly proof Laboratory animal unit with ambient temperature (26-28°C) and adequate ventilation at the Department of Pharmacognosis, University of Benin, Benin City, Nigeria were used for this study. They were fed with standard growers mash (Vita Feeds Nig. LTD), and clean tap water was provided *ad libitum*. The animal study was used in accordance with National Research Council (NRC) Guide for the care and use of Laboratory Animals^[7]. The rats were selectively assigned to group (A, B, C, D and E) n=6.

2.4 Study Design

The animals were subjected to empirical and physical measurements before the commencement of the experimental study and at termination^[8]. Hand towel was used to pick the rats one at a time while oral cannula was used to administer appropriate concentrations of the extract to the rats in group (A, B, C and D) ranging from (50, 200, 350 and 500mg/ml) by oral administration for 30 days at 2day interval, with respect to the L.D₅₀ of 562.3 mg/kg body weight in mice by intraperitoneal route^[9]. Meanwhile group E served as the untreated group (control).

2.5 Grossing and Tissue processing

At the termination of the experimental study, all the animals (treated and untreated) were sacrificed by (chloroform) anaesthetization. The visceral organs of interest (liver and kidney) were excised and observed grossly. They were cut at 3-5mm and were processed by the use of an automatic tissue processor (Hestion - ATP7000 tissue processor-Germany) for dehydration, clearing, and impregnation. After embedding, sections were obtained at 3-5microns using digital rotary microtome (Hestion ERM 4000 Germany).

2.7 Photomicrography

Mayer's haematoxylin and eosin stained sections were examined using the Swift^(R) binocular microscope® (Olympus England) with an in-built lighting system at x10 and 40 magnifications. Histopathological scoring was reviewed by two or more pathologist at the University of Benin Teaching Hospital (UBTH), Benin City, Nigeria.

2.5. Location and Duration of Study

The experimental study was conducted in the animal house of the Department of Pharmacognosis, Faculty of Pharmacy, University of Benin, Benin City, Nigeria. The histological investigation was carried out at the Department of Medical Laboratory Science, Histopathology Sub-Departmental Laboratory, School of Basic Medical Science, University of Benin, Benin City, Nigeria. The study lasted between December 2014 and April, 2015.

2.6 Statistical Analysis

Values were presented in means \pm S.E.M., data were subjected to a two-tailed Student's t-test using Minitab statistical software (version 18.0). A confidence level exhibited at $p < 0.05$ was considered statistically significant.

III. RESULTS

The results obtained in this study revealed that physical signs of gross behavioral changes were not observed in the duration of the study. Empirical measurements of the low dose treated animals (50mg/ml) showed a negligible weight gain (Figure 1 & 2) when compared to the increase and progressive weight loss

observed in the high dose (350 and 500mg/ml) treated animals (Figure 3). Gross examination of the visceral organs (liver and kidney) of both treated and untreated rats were normal in coloration, size, and consistency when compared to untreated groups. In addition, histological indices (cyto-architectures) were of normal histological representation of the visceral organs examined when matched with the untreated rats for comparison (Table 1 & 2). Though, there appears to be negligible signs of vacuolation in the central vein with marked presence of lysed red blood cell observed in the high dose treated rats (500mg/ml) and negligible increase in glomeruli tuft and urinary pole of the renal corpuscle which were thought to be dose dependent or dose-related offenses (Figure 4).

IV. TABLES AND FIGURES

Table 1: Hepatocellular indices of male Wistar rats treated with *A. torta* leaf extract

Group	Dose in mg/ml	Effects on the sinusoid	Inflammatory / cellular infiltration	Inflammatory cell / distortion of bile duct	Hepato cellular necrosis / enlarged hepatocyte	Congested /Distorted /enlarged Central Vein	Vacuolation of the central vein
A	50	-	-	-	-	-	-
B	200	-	-	-	-	-	-
C	350	-	-	-	-	-	-
D	500	-	-	-	-	-	±
E	000	-	-	-	-	-	-

Table 2: Renal indices of male Wistar rats treated with *A. torta*.

Group	Dose in mg/ml	Increase in the urinary pole.	Inflammatory cell infiltration / or Necrosis	Increase / or congested proximal / or distal convoluted tubules.	Erosion or congestive / congested glomeruli tuft	Increase /or congested renal corpuscles	Increase in visceral space of renal corpuscle
A	50	-	-	-	-	-	-
B	200	-	-	-	-	-	-
C	350	-	-	-	-	-	-
D	500	±	-	-	-	-	±
E	000	-	-	-	-	-	-

Key to histological scoring:

+ = Presence of features, ± = Intermediate features,, ++ = Marked presence of features,, - = Absence of features.

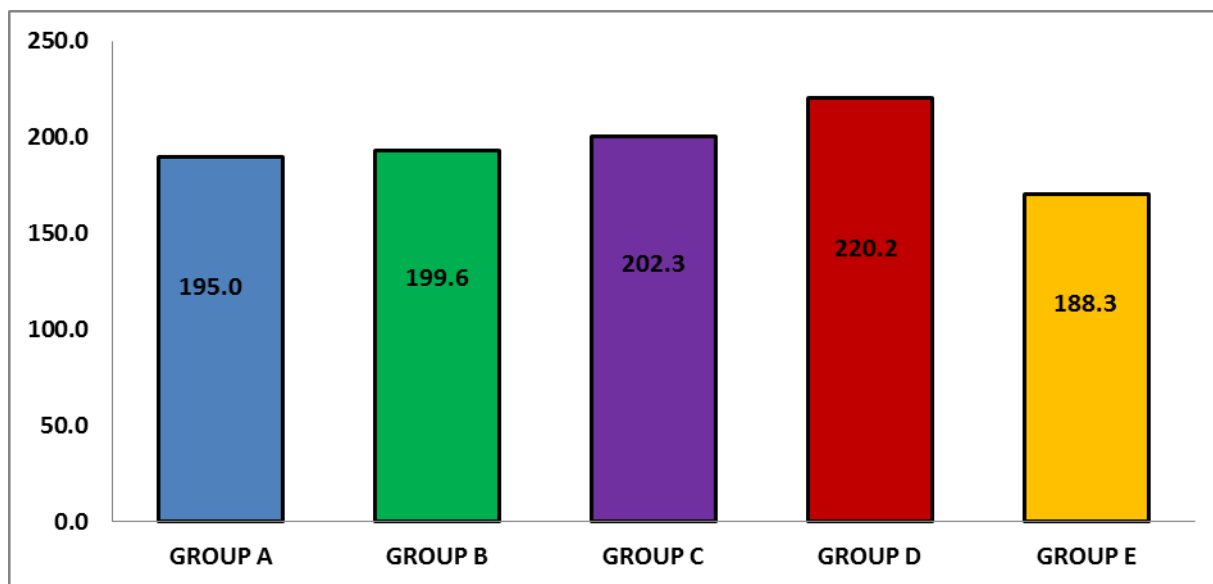


Figure 1: Data presented in means \pm standard error of mean showed the initial weight of the treated and untreated experimental rats. A two-tailed student's t-test indicated lack of significant differences between the mean weights of group A (195.02 ± 1.3), group B (199.56 ± 1.4), group C (202.26 ± 1.2), group D (220.18 ± 1.2) and untreated group E (188.24 ± 1.6) respectively.

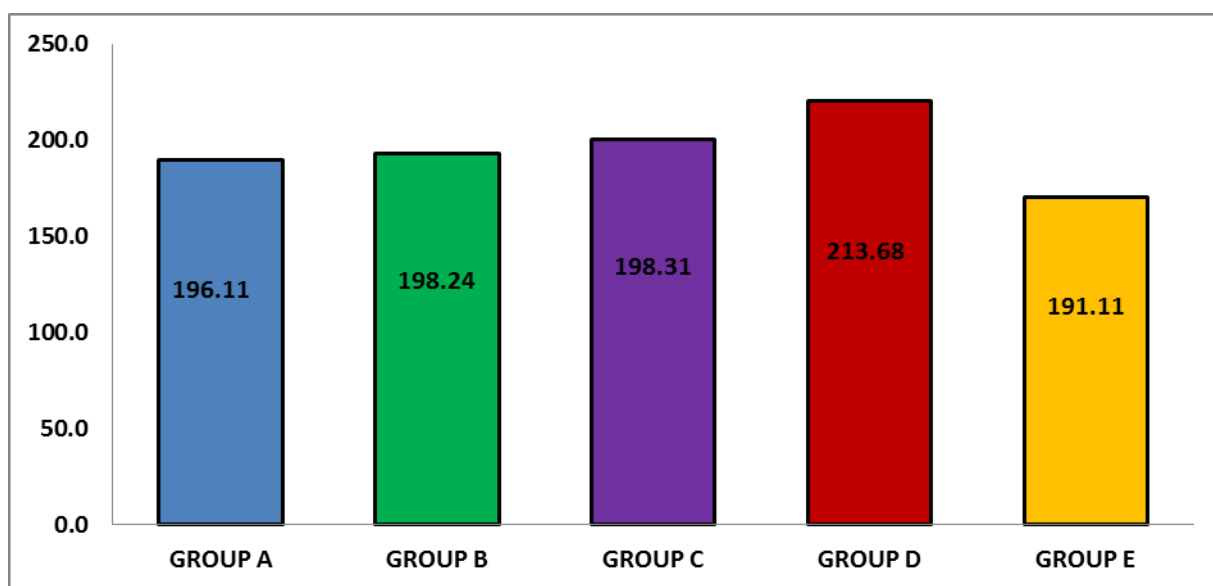


Figure 2: Data presented in means \pm standard error of mean showed the final weight of the treated and untreated experimental rats. A two-tailed Student's t-test indicated lack of significant differences between the mean weights of group A (196.11 ± 2.1), group B (198.24 ± 2.1), group C (198.31 ± 1.1), group D (213.68 ± 1.3) and untreated group E - (191.11 ± 1.4) respectively.

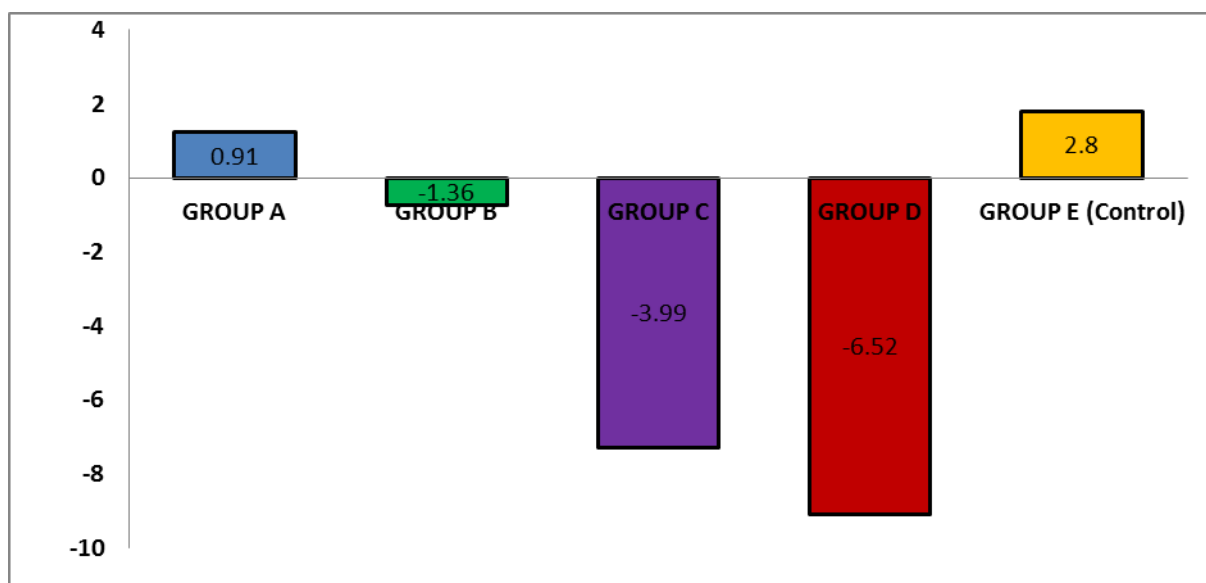


Figure 3: Data presented in means \pm standard error of mean showed weight gain of the untreated rats, negligible weight gain in the low dose treated rats (50mg/ml) and a progressive weight loss in high dose treated rats (200, 350 and 500mg/ml). A two-tailed Student's t-test indicated a lack of significant differences between the mean weights of group A (+0.91), group B (-1.36). However, group C (-3.99), group D (-6.52) and untreated group E (+2.8) showed a considerable level of significance ($p > 0.62$; $p > 0.88$) respectively.

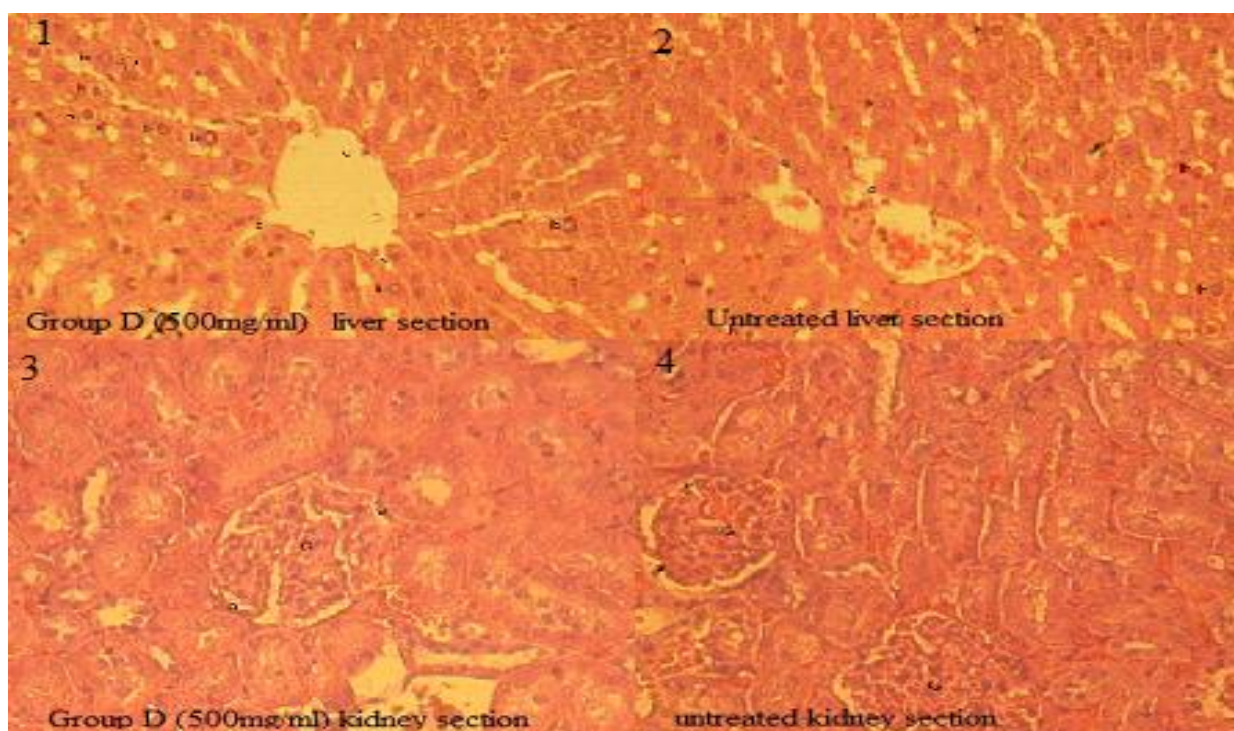


Figure 4: Section (1) treated rat's liver (500mg/ml b.w. oral administration) of *A. torta* extract showed normal histology, with the hepatocyte (h) and the sinusoid (s). Section (3) treated with high-dose (500mg/ml b.w. oral administration) of *A. torta* extract showed normal histology of the kidney (Cortex) with the glomerulus (G), parietal layer (p) and the visceral layer (v). Sections (2 & 4) were untreated groups for assessment. Stain uptake: Mayer's H&E X40 magnification.

V. DISCUSSION

Therapeutic applications of herbal preparations are prevalent in many countries of the world^[10, 11]. Herbal drugs, though natural, can cause serious adverse effects on the body, ranging from cancer to dysfunctions of vital organs such as the liver, kidney, heart, lung and even death^[12]. They could produce a wide range of deleterious effects especially where the plant extract is employed for the management of chronic diseases such as hypertension and diabetes mellitus^[9]. In view of the multifunctional morphological makeup of the liver and kidney respectively, it is important to examine critically these unique and vital visceral organs^[13]. As the case may be, the liver is especially important for maintaining a normal blood glucose concentration, synthesis and metabolism of fat and protein;^[14] the kidneys in turn, are highly vascularized compound tubular glands that function to maintain the composition of body fluids at a constant level and to remove excretory wastes^[15]. Therefore, it becomes paramount to examine these organs (liver and kidney) so as to avoid a sudden breakdown at the cellular level as a result of indiscriminate consumption of herbal preparations.

There appears to be scant or no information documented on the histological adverse effects of *A. torta* leaf extract in rats following oral administration that could act in human in a similar circumstance. In the present study, *A. torta* leaf extract does not have deleterious effects on the visceral organs of rats at a dose of 500mg/ml. This result does not agree with^[9] whereby prominent histological changes were found in the liver and kidney of rats treated intraperitoneally for 28 days. However, these observations may be due in part to either dose relativity or the route of administration.^[13] Recall that higher doses of the extract of *A. torta* in the former (2000mg/kg) were administered intraperitoneally while doses from the latter (present study) were a lower oral dose (500mg/ml).

Furthermore, it has been revealed that body weights of Wistar rats on herbal preparations used as experimental animals observed a significant decrease in weight in relation to increase in concentration of the extract^[14]. The effects produced may be related to dose rate and duration of exposure. The present study is in agreement^[13] by which rats treated with high dose (200, 350 and 500mg/ml) showed a similar decrease in weight of experimental rats (Figure 3). In buttress of the above, our study agrees with the report; that an increased intake of medicinal herbs among men over a period of 6 months caused a decrease in their body weight^[16]. The fact that there appears to be a loss of weight in experimental rats does not signify effects from the extracts of the experimental leaf. It may be as a result of partial / or total withdrawal of the animals from feeds, if the extract administered is not palatable (does not go down well with the rats).

In view of the on-going, it is quite obvious that doses as high as 500mg/ml in this study is not sufficient to cause pathological changes in rats. Though^[7] reported that the acute toxicity (LD₅₀) of *A. torta* extract in mice (562.3 mg/kg body weight) may not be regarded as an ideal index for toxicity since this parameter is dependent on the species of animal used as well as inherent physiological variations, but may act as baseline data for sub-lethal dose manipulations. The observed L.D₅₀ reported^[7] where carried out on albino mice weighing (16-35g) which is in no doubt smaller in body weight when compared to Wistar rats (180-225g) used in the present study.

VI. CONCLUSION AND RECOMMENDATION

From the previous, therefore, our study suggest that oral administration of *A. torta* leaf extract is safe at a lower dose (500mg/ml) than intended to be used for humans. It indicates no histological relevant alterations in the liver and kidney of the test animals administered orally. This result provides support for the safety profile of *A. torta* herbal administration in lower concentrations. However, standard scientific, safe dose regimen by herbal practitioners remains in doubt.

VII. ACKNOWLEDGEMENT

Authors are thankful to the staffs of the Department of Pharmacognosy, Faculty of Pharmacy, University of Benin, Nigeria; for their enormous cooperation and assistance. They are grateful to the management for providing infrastructure, research and laboratory facility for carrying out animal experimental study in compliance with the US National Research Council (NRC) Guide for the care and use of Laboratory Animals. We also send our unreserved appreciation to the pathologist at UBTH Benin City, Nigeria, for a prompt review of histology slides.

REFERENCES

- [1]. T. Okoko and S. Ndoni, The effect of *Garcinia kola* extract on lipopolysaccharide-induced tissue damage in rats. *Tropical Journal of Pharmaceutical Research*, 2009; 8(1): 27-31
- [2]. R. Yerra, G. Malaya and K.M. Upal, *In Vitro* Lipid Peroxidation and Antimicrobial Activity of *Mucuna pruriens* Seeds. *Iranian Journal of Pharmacology and Therapeutics*, 2005; 4:32-35.
- [3]. J.O. Adebayo and A.U. Krettli, Potential antimalarials from Nigerian plants: A review. *J. Ethnopharmacol.* 2011; 133 (2): 289-302
- [4]. G.M. Cragg, D.G. Newmann and K.M. Snader, Natural products in drug discovery and development, *Journal of Natural Products* 1997, 60: 52-60.
- [5]. S. K. Adesina, O. Idowu, A.O. Ogundaini, H. Oladimeji, T.A. Olugbade and G.O. Onawunmi, Antimicrobial constituents of the leaves of *Eacalypha wilkesiana* and *Acalypha hispida*. *Phytother Res.* 2000; 14: 371-4.
- [6]. B.E. Odigie, Histological effects of pre-exposure prophylactic consumption of sulfa drugs on Liver and Kidney of albino Wistar rats (*Rattus norvegicus*). *IOSR Journal of Pharmacy and Biological Sciences*, 2013; 5(6):14-19.
- [7]. National Research Council, Guide for the Care and Use of Laboratory Animals, National Academic Press, Washington DC, 1996.
- [8]. B.E. Odigie and P.U. Achukwu, Morphometric and Histopathological Evaluation of Selected Organs of Albino Rats Following Subcutaneous Administration of *Acalypha wilkesiana* Leaf Extract. *Annals of Biomedical Science*, 2015; 14(1): 131-137.
- [9]. C.N. Ezekwesili, O. Obidoa, O.F.C. Nwodo and J.O. Ezekwesili-ofili, Toxicity of *Acalypha torta* (Muell) leaves ethanolic extract in mice and rat. *Animal Research International*. 2011; 8(1):1315-1322.
- [10]. M.R. Venukumar and M.S. Latha, Hepatoprotective effect of a metabolic extract of *Cuculigo ordchioides* in CCL4-treated male rats. *Indian Journal of Pharmacology*, 2002; 34: 269-275.
- [11]. G. Malaya, U.K. Mazunder, J.S. Kumar, P. Gromathi and R.S. Humar, Antioxidant and hepatoprotective effect of *Buhinia racemosa* against paracetamol and carbon tetrachloride-induced liver damage in rats. *Iranian Journal of Pharmacology and Therapeutics*, 2004; 3:12-20.
- [12]. C. Aschwanden, Herbs for health, but how safe are they? *Bulletin of World Health Organization*, 2001; 79 (7): 691-692.
- [13]. B.E. Odigie and J.O. Odigie, Histo-morphological Examination of the Visceral Organs of Albino Wistar Rats pre-exposed to *Ocimum gratissimum* Crude Decoction. *International Journal of Pharmaceutical Science Invention*, 2014; 3(5): 36-41.
- [14]. A.J. Ajibade, P.B. Fakunle, L.O. Ehigie and A.O. Akinrinmade, Sub-Chronic Hepatotoxicity in Adult Wistar Rats Following Administration of *Ocimum gratissimum* Aqueous Extract. *European Journal of Medicinal Plants*, 2(1), 2012: 19-30.
- [15]. William JB, Linda MB. *Color atlas of veterinary histology* 2nd (Ed), Lippincott, Williams and Wilkins 2000.
- [16]. J.A. Valey, A.T. Proudfoot and T. Lancet, Nutritional values of medicinal herbs. *American Journal of Clinical Nutrition*, 42, 1995; 289-295.