

Duplication of the External Auditory Canal—An Incidental Finding

Shuaib Kayode Aremu, FWACS¹ 

A 25-year-old who presented in our facility with 2 weeks history of right-sided mild otalgia associated with fluctuating hearing loss and ear itching. No otorrhoea, tinnitus, nor vertigo.

Fiber-optic endoscopic otoscopy done revealed an impacted wax in the right ear and normal otoscopy in the left ear. She had aural syringing done, and a repeated otoscopy revealed a dual external auditory canal (EAC; Figure 1). Both canals ended at the tympanic membrane, which was dull and retracted. The patient felt a great relief in the symptoms after the syringing. She was followed up for 3 months without any untoward complication.

External auditory canal develops from the groove of the first branchial arch. This groove deepens and meets the tubotympanic recess of the endoderm and mesoderm contributes from the sides. The plate of tissue thus formed is called a meatal plug, this recanalizes and the EAC is formed. This in-utero recanalization process has a variable outcome and may produce a variation in the lumen of the EAC. Plus during the course of development, the EAC descends downward creating further angulations of the canal.¹

First branchial cleft anomalies are relatively uncommon congenital malformations of the head and neck, accounting for less than 10% of all branchial anomalies, and can be roughly classified as cysts, sinuses, and fistulae.² First branchial cleft anomalies are the result of abnormal embryogenesis and arise from incomplete closure of the ventral portion of the first branchial cleft. Whether the defect is a fistula, sinus, or cyst depends on the degree of closure.³ The anomaly begins on the floor of the EAC in the cartilaginous portion or the bony-cartilaginous junction and ends somewhere in the submandibular region depending on the extent of the anomaly of the fusion.⁴ First branchial arch anomalies have been classified into 2 types. Type-1 anomaly is of ectodermal origin, manifests as cyst or sinus in the parotid gland, and appears during early or middle adult life.^{5,6} Type 2 defects are the ectodermal and mesodermal origin, containing skin with adnexal structures as well as cartilage, and are associated with a sinus/fistula in the anterior triangle of the neck, with a communicating tract to the EAC manifesting during childhood.^{5,6}

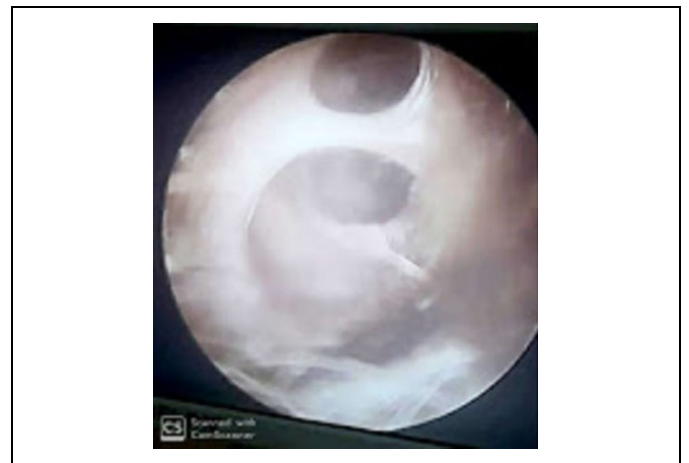


Figure 1. Duplicate external auditory canal and dull retracted tympanic membrane.

The structures derived from the first branchial cleft are cavum conchae, the EAC, and the external layer of the tympanic membrane.⁷ First branchial cleft anomalies are the result of incomplete fusion of ventral portion of the first and second arches.⁷ Congenital anomaly of the EAC is a relatively rare clinical entity and consists of a series of malformations of the auricle and EAC, the latter varying from slight narrowing to complete absence of the EAC.^{8–12} Ultimately, thorough knowledge of the anatomy and embryology of the area combined with a high degree of clinical suspicion appears to be the key factors of an early and accurate diagnosis.

¹ ENT Department, Federal Teaching Hospital Ido-Ekiti, Afe-Babalola University/Ado-Ekiti, Nigeria

Received: June 15, 2019; revised: July 15, 2019; accepted: July 29, 2019

Corresponding Author:

Shuaib Kayode Aremu, FWACS, ENT Department, Federal Teaching Hospital Ido-Ekiti/Afe Babalola University, Ado-Ekiti, Nigeria.

Email: shuaib.arem@gmail.com



Radiological examinations can be helpful diagnostically, in order to determine the typical anatomical localization, the extent, the size, and the relationship of the lesions to surrounding structures. Magnetic resonance imaging allows assessment of the extent of the anomaly, especially in the parotid area, and high resolution-computed tomography imaging shows its exact relationship with the EAC and the middle ear. Fistulas and sinuses are not always obvious on computed tomography and fistulogram can be useful.¹³

Differential diagnosis of first branchial cleft anomalies must be made mainly with second branchial cleft anomalies. Parotid branchial cleft cysts, in particular, must be differentiated from any cystic mass of the parotid.^{14,15} To my knowledge, duplicate EAC is a rare condition with only few reported in the literature, and this is the first been seen in our facility.


Declaration of Conflicting Interests

The author(s) declared no potential conflicts of interest with respect to the research, authorship, and/or publication of this article.

Funding

The author(s) received no financial support for the research, authorship, and/or publication of this article.

ORCID iD

Shuaib Kayode Aremu  <https://orcid.org/0000-0002-0165-6867>

References

- Peter JW. Clinical examination of the ears and hearing. In: Michael Gleeson Edward Arnold ed. *Scott-Brown's Otorhinolaryngology, Head and Neck Surgery*. 7th ed. 2008:3311. Chapter 235.
- Olsen KD, Maragos NE, Weiland LH. First branchial cleft anomalies. *Laryngoscope*. 1980;90(3):423-436.
- Benson MT, Dalen K, Mancuso AA, Kerr HH, Cacciarelli AA, Mafee MF. Congenital anomalies of the branchial apparatus: embryology and pathologic anatomy. *Radiographics*. 1992; 12(5):943-960.
- Triglia JM, Nicollas R, Ducroz V, Koltai PJ, Garabedian EN. First branchial cleft anomalies: a study of 39 cases and a review of the literature. *Arch Otolaryngol*. 1998;124(3): 291-295.
- Work WP. Newer concepts of first branchial cleft defects. *Laryngoscope*. 1972;82(9):1581-1593.
- Whetstone J, Branstetter BF, Hirsch BE. Fluoroscopic and CT fistulography of the first branchial cleft. *Am J Neuroradiol*. 2006;27(9):1817-1819.
- Belenky WM, Medina JE. First branchial cleft anomalies. *Laryngoscope*. 1980;90(1):28-39.
- Jahrsdoerfer RA, Yeakley JW, Aguilar EA, Cole RR, Gray LC. Grading system for the selection of patients with congenital aural atresia. *Am J Otol*. 1992;13(1):6-12.
- Lambert PR. Congenital aural atresia: stability of surgical results. *Laryngoscope*. 1998;108(12):1801-1805.
- Schuknecht HF. Congenital aural atresia. *Laryngoscope*. 1989; 99(9):908-917.
- Mehra YN, Dubey SP, Mann SB, Suri S. Correlation between high-resolution computed tomography and surgical findings in congenital aural atresia. *Arch Otolaryngol Head Neck Surg*. 1988;114(2):137-141.
- Mayer TE, Brueckmann H, Siegert R, Witt A, Weerda H. High-resolution CT of the temporal bone in dysplasia of the auricle and external auditory canal. *AJNR Am J Neuroradiol*. 1997;18(1): 53-65.
- Harnsberger HR, Mancuso AA, Muraki AS. Branchial cleft anomalies and their mimics: computed tomographic evaluation. *Radiology*. 1984;152(3):739-748.
- Agaton-Bonilla FC, Gay-Escoda C. Diagnosis and treatment of branchial cleft cysts and fistulae. A retrospective study of 183 patients. *Int J Oral Maxillofac Surg*. 1996;25(6):449-452.
- Choi SS, Zalzal GH. Branchial anomalies: a review of 52 cases. *Laryngoscope*. 1995;105(9):909-913.