



ISSN: 0976-3031

Available Online at <http://www.recentscientific.com>

CODEN: IJRSFP (USA)

International Journal of Recent Scientific Research  
Vol. 10, Issue, 07(I), pp. 33908-33912, July, 2019

**International Journal of  
Recent Scientific  
Research**

DOI: 10.24327/IJRSR

## Research Article

### PHARYNGO-OESOPHAGEAL FOREIGN BODIES: OUR EXPERIENCE AT TWO FEDERAL HEALTH INSTITUTIONS IN NIGERIA

Gabriel Toyé Olajide<sup>1</sup>., Paul Adebisi Eletta<sup>2</sup>., Waheed Atilade Adegbi<sup>3</sup>., Shuab Kayode Aremu<sup>4</sup> and Musiliu Adejare Lawal<sup>5</sup>

<sup>1,4</sup>ENT Department, Federal Teaching Hospital Ido-Ekiti/AfeBabalola University, College of Medicine and Health Sciences, Ado-Ekiti/Nigeria

<sup>2</sup>ENT Department, Federal Medical Center, Bida, Niger State

<sup>3</sup>ENT Department, Ekiti State University Teaching Hospital, Ado Ekiti, Nigeria

<sup>5</sup>Mental Health Department, Federal Teaching Hospital Ido-Ekiti /AfeBabalola University, Ado Ekiti, Nigeria

DOI: <http://dx.doi.org/10.24327/ijrsr.2019.1007.3779>

#### ARTICLE INFO

##### Article History:

Received 12<sup>th</sup> April, 2019

Received in revised form 23<sup>rd</sup> May, 2019

Accepted 7<sup>th</sup> June, 2019

Published online 28<sup>th</sup> July, 2019

##### Key Words:

Foreign bodies, Pharyngo-oesophageal, health institution, complications, Nigeria

#### ABSTRACT

**Background/Aim:** Foreign bodies (FBs) of the upper aero digestive tract often present as medical emergencies and it is common in children especially under the age of five years. The aim of this study was to present our experience with the management of Pharyngo-oesophageal FBs in two federal health institutions in Nigeria over a 10-years period.

**Methods:** It was a retrospective study. Records of all the patients with pharyngo-oesophageal foreign bodies who were seen and treated in the Accident and Emergency unit and ENT clinic was retrieved from the hospital medical record department. The information that was extracted include their demographic data, time of ingestion to presentation, presenting symptoms, type of FB ingested, treatment, length of hospital stay and outcome. X-ray soft tissue of the neck (anteroposterior and lateral views) of the patients was also reviewed.

**Results:** A total of 57 patients have complete data for this study. There were 43 males and 14 females given a male to female ratio of 3:1. Their age range was 9 months to 86 years with a mean of  $32.8 \pm 23.4$ SD. Majority (38.6%) of the patients are in the age range of 0-20 years. At presentation, their major complaints were dysphagia (89.5%) and odynophagia (84.2%). More than half of the patients (57.9%) presented within 24 hours of ingestion of foreign body. The most common ingested foreign body was dentures, which were noted in 18(31.6%) patients. All patients except one had rigid endoscopy. More than half (61.4%) of the FB impaction was seen at the upper third of the oesophagus. Complications recorded are failed procedures in 3 (5.3%) patients, foreign bodies were not seen in 2(3.5%) patients and one (1.8%) had subcutaneous emphysema.

**Conclusion:** Accidental foreign body ingestion of the oesophagus was still a major problem among children. Commonest foreign object recorded in this study was denture. Large percentages of FBs ingested were at home. Rigid oesophagoscopy removal is still the safest method of treatment. Health education as to its prevention and early presentation to health facility will prevent morbidity and mortality

Copyright © Gabriel Toyé Olajide *et al*, 2019, this is an open-access article distributed under the terms of the Creative Commons Attribution License, which permits unrestricted use, distribution and reproduction in any medium, provided the original work is properly cited.

#### INTRODUCTION

Foreign body (FB) impaction in the upper aerodigestive tract is relatively common in Otorhinolaryngological practice. It is commonly seen in children. These children by their nature, curiosity, and inquisitive; explore the various orifices in the body<sup>1,2</sup>. Also tendency to cry, shout, laugh or play while eating and availability of these objects are other factors that may encourage ingestion of foreign body in children<sup>2,3</sup>. Foreign

body impaction in the pharynx or oesophagus may also be seen in adults who are mentally retarded or deranged or deliberately swallowed as in charm rituals or self-harm as in suicidal attempts<sup>4,5,6</sup>. A wide variety of objects are often implicated, such as toy parts, coins, needles, bones, pins, plugs or dental appliances<sup>7,8</sup>. Wide varieties of foreign bodies (FBs) lodging in the upper aerodigestive tract and a large number of complications have been reported in literatures<sup>9,10</sup>. The diagnosis of a foreign body in the pharynx or oesophagus may

\*Corresponding author: Gabriel Toyé Olajide

ENT Department, Federal Teaching Hospital Ido-Ekiti/AfeBabalola University, College of Medicine and Health Sciences, Ado-Ekiti/Nigeria

pose a problem, particularly when the history is not reliable or not forthcoming, and parents/caregivers are not even sure of what the child might have ingested. Radiological investigation should therefore be carried out in all patients with suspicion of upper aerodigestive foreign bodies ingestion, especially when it is available, affordable and patient's clinical condition permits. Apart from absence of history of foreign body ingestion, occasionally timely diagnosis may be delayed by absence of classical symptoms, predominance of respiratory symptoms and ingestion of radiolucent foreign bodies<sup>11,12</sup>. In this environment, delayed presentation in the hospital, financial handicap, sparse distribution of personnel (specialist) and facilities may add to the delay in diagnosis as well as in removal of the foreign bodies<sup>13</sup>. The choice of procedure to remove foreign body in the upper aerodigestive tract will depend on the exact location, its shape, size, nature, duration of impaction and the skill of the surgeon<sup>14,15</sup>. Almost with out exception, the treatment of choice for foreign bodies of the upper aerodigestive tract is reasonably prompt endoscopic retrieval in the operating suite under general anesthesia. There is paucity of report of pharyngo-oesophageal FBs in our region hence this study aimed to review our experience with the management of pharyngo-oesophageal FBs over a 10-years period in two tertiary health institutions.

**MATERIALS & METHODS**

This is a 10-year retrospective study of patients with pharyngeal and oesophageal foreign bodies seen and treated at the Ear, Nose and Throat departments of two health institutions in Ekiti and Niger state, both in Nigeria from July 2008 to June 2018. Records of all the patients with pharyngo-oesophageal foreign bodies who were seen and treated in the Accident and Emergency unit and ENT clinic was retrieved from the hospital medical record department. The information that was extracted include their demographic data, time of ingestion to presentation, presenting symptoms, type of FB ingested, treatment, length of hospital stay and outcome. Radiological investigations (X-ray soft tissue of the neck (anteroposterior and lateral views) of all patients was reviewed. Some patients had chest x - ray and an abdominal x-ray done where necessary especially when the FB seemed to have migrated. Inclusion criteria include all patients with complete records/data. Exclusion criterion includes patients with incomplete data, patients that were seen in A&E and were asymptomatic and with normal radiological findings. Ethical approval to conduct this study was obtained from the hospital ethics and research committee. A simple descriptive analysis of the data obtained was done using SPSS version 20.0 and presented in simple tables and charts.

**RESULTS**

A total of 57 patients have complete data for this study. There were 43 males and 14 females given a male to female ratio of 3:1. Figure 1. Their age range was 9 months to 86 years with a mean of 32.8 ± 23.4SD. Majority (38.6%) of the patients are in the age range of 0-20 years. Figure 2. Thirty seven (64.9%) of them are Christian while 35.1% practiced Islam. More than half of them (56.1%) are not in the working class (children, students and unemployed). At presentation, their complaints were dysphagia (89.5%), odynophagia (84.2%), drooling saliva (28.1%), neck pains (19.3%), throat discomfort (10.5%) and

chest pain (5.3%). Table 1. The time interval of ingestion to presentation varied. More than half of the patients (57.9%) presented within 24 hours of ingestion of foreign body whereas 35.1% presented within one week. Figure 3. The most common ingested foreign body was dentures, which were noted in 18(31.6%) patients. Other common foreign bodies noted were bones from fish and chicken in 11(19.3%) patients, meat bolus in 8(14.0%), coins in 6(10.5%). Table 2. Large percentage (70.2%) of FB were ingested at home, 9(15.8%) was ingested in the school. Twenty (36.8%) of the FB was ingested while eaten, 31.6% when attempted to take their drugs, 26.3% while playing with object, 3.5% during sleep while 1.8% occurred when the patient was trying to keep a live fish caught in his mouth. All patients except one had rigid endoscopy for removal. More than half (61.4%) of the FB impaction was seen at the upper third of the oesophagus, 35.1% were seen at the level of cricopharyngeal sphincter while 3.5% was impacted at the oropharynx. Thirty nine (68.4%) spent less than 72 hours on admission, 17.6 % spent one week while 14.0% were discharged between 1-2 weeks. Complications recorded are failed procedures in 3 (5.3%) patients, foreign bodies were not seen in 2(3.5%) patients and one (1.8%) had subcutaneous emphysema.

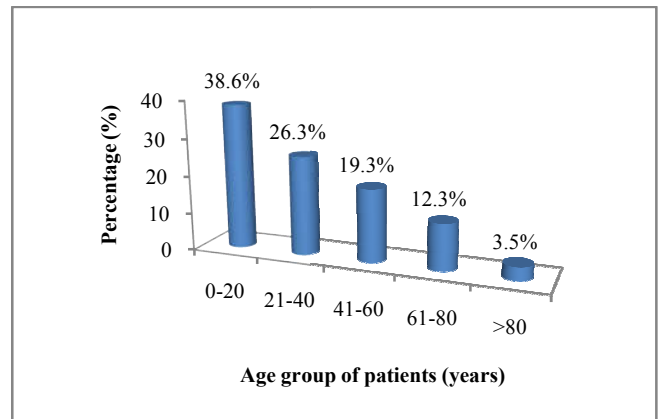


Figure 1 Showing Age group of the patients

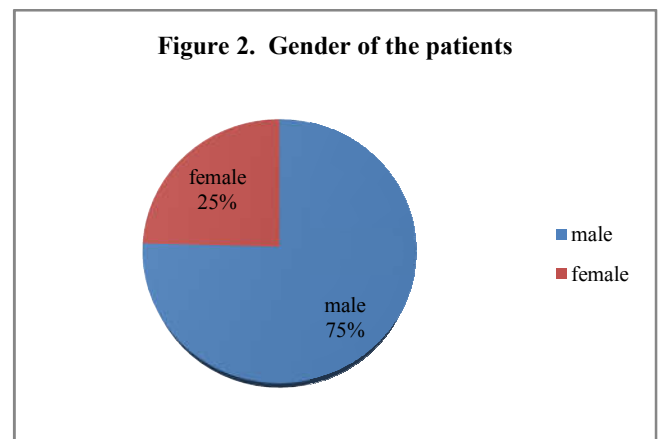


Figure 2. Gender of the patients

Table 1 Showing symptoms at presentation

Symptoms	Frequency (n)	Percentage (%)
Dysphagia	51	89.5
Odynophagia	48	84.2
Drooling of saliva	16	28.1
Neck pains	11	19.3
Throat discomfort	6	10.5
Chest pain	3	5.3

NB: Some patients presented with more than one symptom

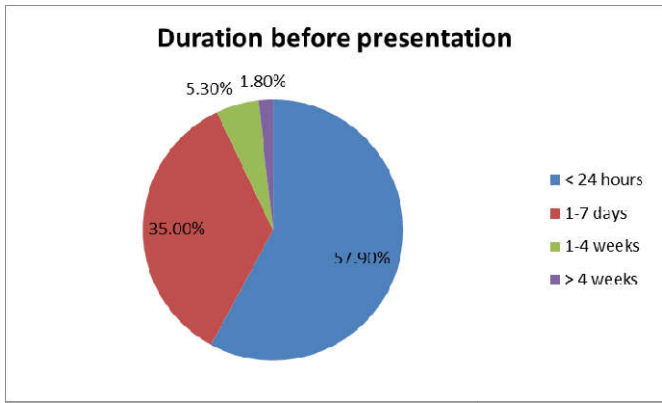


Figure 3 Showing duration before presentation by patients

Table 2 Showing type of foreign body (n=57)

Foreign body	Frequency (n)	Percentage (%)
Denture	18	31.6
Bone (fish, meat)	11	19.3
Meat bolus	8	14.0
Coins	6	10.5
Metallic object	3	5.3
Battery button	2	3.5
Plastic toy part	2	3.5
Tooth pick	2	3.5
Razor blade part	1	1.8
Kola nut	1	1.8
Ear ring	1	1.8
A whole fish	1	1.8
cork of soft drink bottle	1	1.8

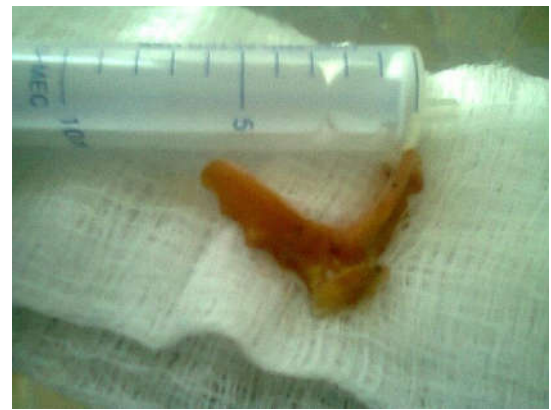

Fig 4 Denture after removal from the esophagus of an adult

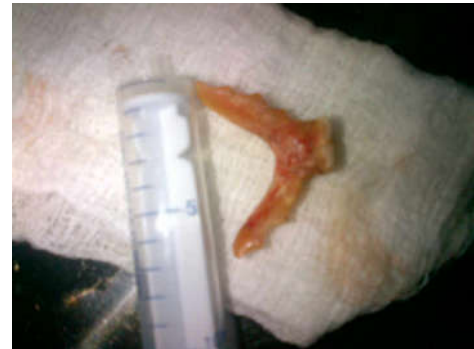

Fig 5 Denture after removal from the esophagus of an adult



Fig 6 Denture after removal from the esophagus of an adult

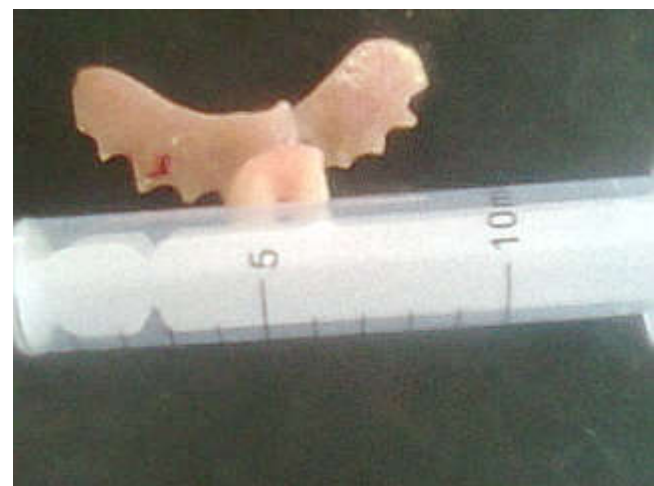

Fig 7 Denture after removal from the esophagus of an adult

## DISCUSSION

Foreign bodies of the upper aero digestive tract often present as medical emergencies- particularly in view of the possibility of a compromised airway<sup>16</sup>. Majority of our patients was found to be within the age group of 0-20 years, out of which 45.5% of them are below age of 5 years showing that FB ingestion was still a common problem at age below 5 years. Similar to reported cases by other authors<sup>17-18</sup>. Apart from their curiosity to explore orifices, children who are not given individual attention and who are left to feed themselves at early age are more liable to swallow a FB as it was noted in this study. Male preponderance was noticed in our study which was similar to findings by other authors<sup>14,19, 20</sup>. Generally it was reported by various authors that male children are more active and inquisitive and tend to explore their environment more than their female counterparts and hence more prone to FB impaction in their orifices<sup>19,21,22</sup>. Majority of our patients were unemployed; this was not surprising as many of them fell within the category of children, students and retirees. The major complaints in our study were dysphagia and odynophagia. Presentation at times may depend on many factors such as age, site, type of the FB ingested, duration of ingestion and underlying pathological conditions<sup>23,24,25</sup>. The time interval to presentation in the hospital after ingestion of FB varied, in our study majority (57.9%) presented within 24 hours of FB ingestion. Alabi *et al* noted that the main determinants of early presentation is the severity of the symptoms especially when there is pains or discomfort, excessive drooling of saliva, odynophagia and dysphagia<sup>26</sup>. It may also be early in children if the FB was ingested in the presence of an adult (parents or care giver).



Fig 8 Metallic object after removal from the oesophagus of a child

Commonest FB ingested in our study was dentures and it occurs mainly in adults. Other researchers reported similar findings in their studies<sup>19,27</sup>. Accidental ingestion of dentures occurred in our patients mostly when they were trying to use their drugs/medication. Only one patient accidentally ingested his own denture during sleep. Risk factors noticed are edentulous patients and ill-fitting dentures. Worn out or lose fitting dentures should be changed periodically. Some author previously recorded coins to be the commonest FBs in their studies<sup>26,28-30</sup>. However only 10.5 % of our patients swallowed coins and they are mainly in children. Our findings are not surprising as the use of coins was gradually faced out from circulation in Nigeria over the years by people. Also some of the coins were converted to naira note which further make them unavailable. The incident of FB ingestion occurs largely at home among our patients. In children the availability of some of the materials in various homes which may be displayed recklessly or use of toy by them or as a means of pacifying them was noted by Adedeji *et al*<sup>19</sup>. In adult it occurred majorly while eating or during an attempt to use drugs prescribed for them by a health practitioner. One of our patients, a member of fishermen who accidentally ingested a live fish which got stucked in the throat as he was trying to keep it in his mouth while trying to catch another fish. Large percentage of our patients were treated and discharged from hospital within 72 hours. Majority (61.4%) of the FBs in our patient were impacted at the upper third of the oesophagus. Radiologic confirmation of FB in the oesophagus may be difficult especially when they are radiolucent, hence tale-tell signs such as widening of the prevertebra space, loss of normal lordosis, air in the oesophagus and tracheal compression may be helpful<sup>19,31</sup>. Only 28.1% of our patients had radiologic confirmation of FB in the oesophagus. Rigid oesophagoscopy procedures were carried out in all our patients except intwopatients; one had a whole fish impaction in the oropharynx, which eventually vomited the fish while awaiting operation. The second patient had fish bone removal by flexible oesophagoscopy. Of those that had rigid oesophagoscopy, 52(91.2%) had successful removal of their FBs. The use of rigid oesophagoscopy in the management of impacted oesophageal foreign bodies has been a challenge since its inception<sup>14</sup>. We used rigid oesophagoscopy majorly in our center with good results and without complications. Rigid oesophagoscopy under general anaesthesia has been regarded as the preferred method of removal despite other various modalities like flexible endoscopy, foley's catheter, digestive enzymes, glucagon, atropine, magnets and forceps<sup>32-34</sup>. Foreign bodies could not be located during endoscopy in two of our patients. Those foreign bodies were suspected to be fish bone

which might have got embedded in the soft tissue when they used hard food bolus to forcefully push the FB down the oesophagus. Complications in this study includes failed procedures in three patients which warrant those patients been referred to other centers. One patient had subcutaneous emphysema which was managed conservatively. Various researchers had also reported different complications such as oesophageal perforation, laceration of oesophageal mucosa, abscess formation in the neck, pneumomediastinum, and mediastinitis<sup>27,35</sup>. No mortality was recorded in our patients. Prompt diagnosis and treatment of foreign bodies trapped in the gastrointestinal tract decreases mortality and length of hospital stay. The limitation to this study was that it is a retrospective in nature, our patients are small in number and also there was no provision for mucosal biopsies, hence patients were not evaluated for a potentially treatable/underline cause.

## CONCLUSION

Accidental foreign body ingestion in the oesophagus was still a major problem among children especially below 5 years. Commonest foreign object recorded in this study was denture. Large percentages of FBs ingested were at home. Rigid oesophagoscopy removal is still the safest method of treatment. Health education as to its prevention and early presentation to health facility will prevent morbidity and mortality.

**Financial support: Nil**

**Conflict of Interest: Nil**

## References

1. Mantooth R. foreign bodies. Ear eMedicine (2007) <http://www.emedicine.com/emerg/TOPIC185.HTM>. Accessed on July 2018
2. Ijaluola GTA, Okeowo PA. Foreign bodies in the ear and its importance: the Nigeria experience. *Journal of Tropical Paediatrics*. 1986;32:4-6
3. Murty PSN, Vijendra SI, Ramakrishma F, Shah V, Phillip D. SQU. *Journal for Scientific Research: Medical Sciences* 2001; (2) :117-120
4. Kalan A and Tariq M. Foreign bodies in the nasal cavities: a comprehensive review of the aetiology, diagnostic pointers, and therapeutic measures: *Postgrad Med J*. 2000; 76:484-487.
5. Werman HA. Removal of foreign bodies of the nose. *Emerg Med Chin North Am*. 1987; 5:253-263.
6. Yagi H.. An unusual foreign body in the oesophagus. *Cent. Afri J Med*.1991; 37(7):222-4.
7. Kurul S, KandoganT. Pharyngeal foreign body in a child persisting for three years-case report. *Emerg Med J*. 2002;19:361-362
8. Okhakhu AL, Ogisi FO. An Unusual foreign body in human oesophagus-Case Report. *Benin Journal of Postgraduate Medicine*. 2007; 9(1): 41-43
9. Vele DD, Dubey SP. An unusual foreign body.A whole fish in the throat. *AurisNasus larynx*.1997; 24:207-9.
10. Okafor BC. Foreign bodies in the pharynx and oesophagus. *Nigerian Medical Journal*. 1979; 9(3): 321-324.

11. Ologe FE, Busari SS, Amole AOD. Impacted radiolucent foreign body simulating retropharyngeal abscess. *Ann Trop Paediatr*. 2004; 24(1):111-2.
12. Haegen TW, Mojtczak HA, Tomita SS. Chronic inspiratory stridor secondary to a retained penetrating radiolucent oesophageal foreign body. *J. Paediatr Surg*. 2003; 38(2):e6.
13. Alabi BS, Ologe FE, Dunmade AD, Segun – Busari S, Olajide TG. Review of Pharyngo – oesophageal foreign bodies’ impaction in a Nigerian Hospital. *Euro Jour of Sci Research*. 2005; 11(3):578-584.
14. Onotai LO, Etawo US. The challenges of Rigid esophagoscopy in the management of esophageal foreign bodies in Port Harcourt. *Int. J. Med. Med. Sci*. 2012; 2(5):108-113
15. Segun-Busari S, Afolabi OA, Alabi BS, Adebola SO. Multiple oesophageal coin-like Foreign Bodies appearing like one: A caution for Otorhinolaryngologist. *Int. J. Med. Med Sci*. 2013; 5(6):247-250. DOI:10.5897/IJMMSO9.395
16. Grochowski JJ, Hynes Brian. A toddler with a pharyngeal foreign body. *Can Family Physician*. 2008;54(12):1695-1696
17. Mahafza T, Batiha A, Suboh M, Khrais. Esophageal foreign bodies: a Jordanian experience. *Int J Pediatr Otorhinolaryngol*. 2002; 64(3):225-7
18. Uba AF, Sowande AO, Amusa YB. Management of oesophageal foreign bodies in children. *East Afr Med J*. 2002; 79(6):334-8
19. Adedeji TO, Haastrup AA. Oesophageal Foreign bodies: An experience with rigid esophagoscopy in a developing country. *East Cent Afr J Surg*. 2014;19:25 - 35
20. Okoye BCC, Erefah AZT. Oesophageal foreign bodies in Port Harcourt. *J. Med. Invest. Pract. (JOMIP)* 2001; 2:62 – 64
21. Okoye BCC, Onotai LO. Foreign bodies in the Nose. *Niger. J. Med*. 2006;15(3): 301-304
22. Onotai LO, Ebong ME. The pattern of foreign body impactions in the tracheobronchial tree in university of Port Harcourt Teaching Hospital. *Port Harcourt Med. J*. 2011; 5(2):130-135
23. Al-Qudah A, Daradkeh S, Abu-Khalaf M. Esophageal foreign bodies. *Eur J Cardiothorac Surg*. 1998; 13(5):494-8.
24. Higo R, Matsumoto Y, Ichimura K, Kaga K. Foreign bodies in the aerodigestive tract in pediatric patients. *AurisNasus Larynx*. 2003; 30(4):397-401.
25. Benjamin SB. Esophageal Foreign Bodies and Food Impactions. *Gastroenterology & Hepatology*. 2008; 4 (8)
26. Alabi BS, Ologe FE, Dunmade AD, Segun-Busari S, Olajide TG. Review of Pharyngo-Oesophageal foreign bodies Impaction in a Nigeria Hospital. *Euro J of Scientific research*. 2005; 11(3):578-584
27. Nwaorgwu OG, Onakoya PA, Sogebi OA, Kokong DD, Dosumu OO. Esophageal impacted dentures. *J. Natl. Med. Assoc*. 2004; 96:1350-1353
28. Iseh KR, Oyedepo OB, Aliyu D. Pharyngo-oesophageal Foreign Bodies: Implications for Health Care Services in Nigeria. *Annals of African Medicine*. 2006;5( 1): 52-55
29. Okafor BC. Foreign Bodies in the pharynx and oesophagus. *Nig. Med. Journal*. 1979;9(3):545-549
30. Odelowo EO, Komolafe OF. Diagnosis, Management and complications and airway Foreign Bodies. *Int. Surg*. 1990;75(3):148-54
31. Salisu A. Sharp and irregular shaped esophageal Foreign Bodies: Outcome of endoscopic extraction in Kano BOMJ 2011;8(1):1-4
32. Hussain G, Iqbal M, Ihsanullah, Hussain M, Ali S. Esophageal Foreign Bodies: An Experience with Rigid Esophagoscopy. *Gomal J Med Sci*. 2010;8(2):218-220
33. Peter A, Mohammed DI, Pattern of Foreign Bodies in the Throat. *Journal of Natural Sciences Research*. 2012; 2(4):8-12
34. Sittirai P, Pattarasakulchai T, and Tapatiwong H. esophageal foreign bodies. *J. Med. Assoc. Thai*. 2000; 83 (12): 1514-1518
35. Khan MA, Hameed A, Choudhry AJ. Management of foreign bodies in the esophagus. *J Coll Physicians Surg. Park*. 2004; 14(4):218-220

**How to cite this article:**

Gabriel Toye Olajide et al. 2019, Pharyngo-Oesophageal Foreign Bodies: Our Experience At Two Federal Health Institutions In Nigeria. *Int J Recent Sci Res*. 10(07), pp.33908-33912. DOI: <http://dx.doi.org/10.24327/ijrsr.2019.1007.3779>

\*\*\*\*\*